

A Case of Autoimmune Cholangitis Misdiagnosed for Cholangiocarcinoma: How to Avoid Unnecessary Surgical Intervention?

Igor I. Ignjatović¹, Slavko V. Mati^{1,2}, Vladimir D. Dugalić^{1,2}, Djordje M. Knežević^{1,2}, Marjan T. Micev^{2,3}, Marko D. Bogdanović¹, Srbslav M. Knežević^{1,2}

¹Department of Hepatobiliary and Pancreatic Surgery, Clinic for Digestive Surgery – First Surgical Clinic, Clinical Center of Serbia, Belgrade, Serbia;

²University of Belgrade, School of Medicine, Belgrade, Serbia;

³Department of Pathology, Clinic for Digestive Surgery – First Surgical Clinic, Clinical Center of Serbia, Belgrade, Serbia

SUMMARY

Introduction Autoimmune cholangitis or immunoglobulin G4-associated cholangitis (IAC) has been recently regarded as a new clinical and histopathological entity and is a part of a complex autoimmune disorder – IgG4-related systemic disease (ISD). ISD is an autoimmune disease with multi-organic involvement, characterized with IgG4-positive plasmocytic infiltration of various tissues and organs with a consequent sclerosis, which responds well to steroid therapy. Most commonly affected organs are the pancreas (autoimmune pancreatitis, [AIP]) and the common bile duct (IAC). IAC and cholangiocarcinoma (CCA) share many clinical, laboratory and imaging findings.

Case Outline We present a case of a 60-year-old male with a biliary stricture of a common bile duct, which was clinically considered as a bile duct carcinoma and treated surgically. Definite histopathological findings and immunohistochemistry revealed profound chronic inflammation, showing lymphoplasmacytic IgG-positive infiltration of a resected part of a common bile duct, highly suggestive for the diagnosis of IAC. In addition, postoperative IgG4 serum levels were also increased.

Conclusion It is of primary clinical importance to make a difference between IAC and CCA, in order to avoid unnecessary surgical intervention. Therefore, IAC should be considered in differential diagnosis in similar cases.

Keywords: autoimmune cholangitis; cholangiocarcinoma; differential diagnosis

INTRODUCTION

Autoimmune cholangitis (IAC) as a part of IgG4-related systemic disease (ISD) was initially described by Sarles et al. [1] on the base of a study of autoimmune pancreatitis (AIP). Concept of ISD was proposed by Kamisawa et al. [2], and it was soon widely accepted and recognized as a new clinical and histopathological entity. The common bile duct and the pancreas are most commonly affected, but other organs may also be involved, such as the gallbladder, retroperitoneal tissue (retroperitoneal fibrosis), kidneys, bowels (inflammatory bowel disease [IBD]), lungs, salivary and/or lacrimal glands (Sjögren's syndrome) and prostate. According to the report by Ghazale et al. [3], the largest IAC study encompassed 53 patients. IAC occurs most commonly in males in the 5th or 6th decade of life. Clinical picture of IAC is dominated by upper abdominal pain and weight loss. Physical examination usually reveals mild to moderate tenderness in epigastrium and/or under the right subcostal arch with or without jaundice. In laboratory findings, there is an elevation of serum IgG4 in majority of cases, liver enzymes and amylase serum level. Elevation of serum CA 19-9 levels are not uncommon. Different imaging techniques (multiple

detector computed tomography [MDCT] / multislice computed tomography [MSCT] or magnetic resonance imaging [MRI] / magnetic resonance cholangiopancreatography [MRCP]) may show bile duct strictures or a pseudotumor formation. Endoscopic retrograde cholangiopancreatography (ERCP) could be of help in obtaining the proper diagnosis, confirmed by histopathology (bile duct forceps / brushing biopsy). Unless interpreted properly, this lesion could be easily mistaken for cholangiocarcinoma (CCA) and patient subjected to an unnecessary surgical procedure. Histopathological analyses usually reveal the true nature of the disease.

CASE REPORT

We present a case of a 60-year-old male, which was admitted to the hospital for a moderate pain under the right costal arch, nausea, upper abdominal discomfort, weight loss of 10 kg in the previous 2 months and jaundice. In laboratory findings, bilirubin (124 µmol/L), AST (165 U/L), ALT (286 U/L) and alkaline phosphatase (164 U/L) serum levels were elevated. However, CA 19-9 serum level was not increased. Abdominal ultrasound examination

Correspondence to:

Igor I. IGNJATOVIĆ
Clinic for Digestive Surgery
First Surgical Clinic
Clinical Center of Serbia
Dr Koste Todorovića 6
11000 Belgrade
Serbia

scubaextreme1111@gmail.com



Figure 1. Postoperative MRI/MRCP imaging showing normal passage of contrast agent and satisfying integrity of hepaticojejunostomy

showed slightly enlarged liver with steatosis and dilatation of intrahepatic bile ducts. Right and left hepatic ducts were 9 mm and 10 mm in diameter, respectively. Common bile duct could not be visualized proximal of the insertion of cystic duct. ERCP could not be performed due to the presence of a large peripapillary diverticulum. Considering the progression of jaundice, weight loss, and worsening of clinical symptoms, surgery was performed. Intraoperatively, scirrhous tumorous thickening of the common bile duct was found, involving cystic duct insertion and extending proximally just below, to the hepatic confluence. Surgical procedure included segmental resection of the common bile duct with proximal transection line just below, to the hepatic confluence. After suture placement on distal common bile duct stump, a hepaticojejunostomy with an isolated jejunal loop (Roux-en-Y) was done, using interrupted, resorbable sutures. Postoperative course was uneventful. Postoperative MRI/MRCP showed no obstruction in the passage of contrast agent and satisfying integrity of hepaticojejunostomy (Figure 1).

Resected common bile duct, measuring 27 mm, on histopathological examination showed extremely narrowed lumen with dense cellular infiltration of the wall with maximal diameter of 12 mm including extramural extension of at least 5 mm. Intensive transmural chronic fibroinflammatory reaction presented heterogeneous although predominant mononuclear composition without lymphoid follicular formation (Figure 2). Destructive duct epithelium changes and obliterative phlebitis were also verified within fibroinflammatory infiltration. Lymphoid cell infiltration presented no elements of pleomorphism, nuclear atypia or high mitotic index. Additional immunohistochemical analysis showed IgG4 immunoreactivity of plasmacytoid cells. Histopathological report was conclusive for IAC which was clinically presented as a pseudotumor of an extrahepatic bile duct. After surgical interven-

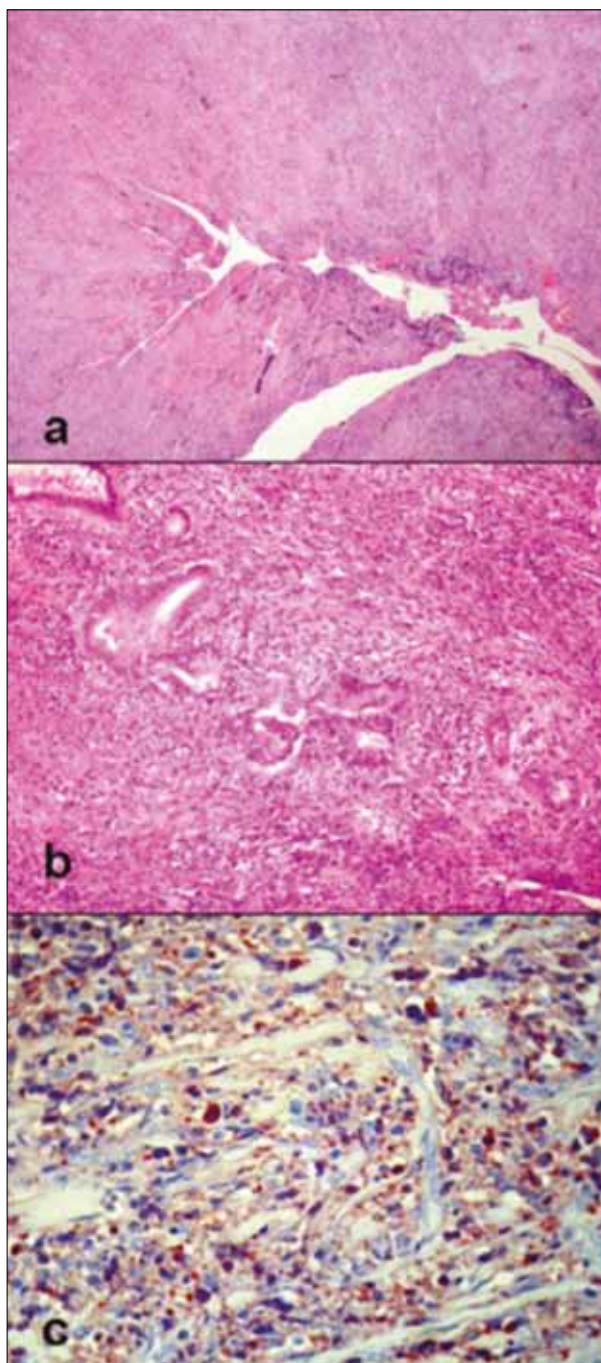


Figure 2. Histopathological findings were consistent with IAC: a) dense fibro-inflammatory infiltration of the choledochal duct with slit-like luminal subocclusion (H&E; 40 \times); b) destructive ductal lesion and obliterative phlebitis (H&E; 200 \times); and c) dominant IgG4 immunoreexpression of infiltrative lymphoid cells (IgG4 monoclonal antibody immunostaining, SAB/AEC visualization kit; 400 \times)

tion, laboratory analyses showed that mean serum IgG4 level was 0.8 g/l (range 0.08–1.4). The patient was further treated by a gastroenterologist with conservative treatment (mainly prednisone) as first line therapy.

DISCUSSION

IAC should be suspected in the presence of an unexplained biliary stricture, increased serum IgG4 and unexplained pancreatic disease. Ghazale et al. [3] proposed HISORT

criteria for establishing a diagnosis of IAC (histology, imaging, serology, other organ involvement and response to therapy). Histologically, there should be a lymphoplasmacytic infiltrate with 10 or more IgG4-positive cells per high-power field within and around bile duct with associated obliterative phlebitis and storiform fibrosis. Imaging (MRCP, MSCT) should reveal one or more strictures involving intrahepatic, proximal extrahepatic or intrapancreatic bile duct; fleeting/migrating biliary strictures. Serology should confirm increased level of serum IgG4. Although being an important feature of IAC, elevated serum IgG4 level does not have a mandatory diagnostic value. Furthermore, Lytras et al. [4] have reported a low sensitivity and accuracy (45% and 58%, respectively) of serum IgG4 level for IAC. Other organ involvement is common finding, such as AIP, retroperitoneal fibrosis, renal lesion, Sjögren's syndrome and IBD. Response to therapy (steroids) is very good in terms of normalizing liver enzyme levels and resolution of biliary stricture. However, complete resolution of stricture may not be seen in all patients, especially those early in the course of treatment (<6 weeks) or with dominantly fibrotic stricture. We would like to emphasize that relapses are common after steroid withdrawal (53%), especially in intrahepatic and proximal extrahepatic strictures [3]. Differential diagnosis of IAC should include both benign and malignant lesions. Benign lesions include primary sclerosing cholangitis (PSC), ischemic damage, pancreatitis, immune deficiency or strictures caused by iatrogenic biliary injury. Malignancies include bile duct carcinoma, gallbladder carcinoma and invasion by pancreatic carcinoma. Differential diagnosis toward CCA can be extremely difficult and is a major clinical issue for surgeons. Most commonly, IAC is misdiagnosed for CCA and unnecessary surgery is performed, such as Whipple's operation, liver resections and segmental biliary resections. In order to avoid unnecessary surgery, by making every effort to distinguish IAC from CCA, attention should be paid to the following clinical facts and observations: 1) with CCA, serum level of IgG4 is usually normal, or seldom mildly elevated while the titers of more than 300 mg/dL are highly suggestive for IAC; 2) bile IgG4 levels are always normal in patients with CCA and elevated only in those with IAC [5]; 3) with CCA, there is often some other underlying biliary disorder which could serve as precancerous lesion such as PSC, chronic biliary infection, choledochal cyst, hepatolithiasis and parasitic hepatobiliary infections; 4) other organ involvement is common with IAC (AIP, Sjögren's syndrome, IBD, retroperitoneal fibrosis, renal lesion) while this is not the case in patients with CCA; 5) with CCA, clinical symptoms such as jaundice, pruritus, malaise and weight loss, are constantly advancing and become only more severe in time, while in IAC, remissions and relapses are often; 6) patients with IAC respond well to steroid therapy which, of course, is not the case with CCA (Table 1).

Since IAC and CCA share common clinical, imaging and laboratory characteristics, IAC is very often interpreted as CCA and patients submitted to unnecessary sur-

Table 1. Comparison of IgG4-associated cholangitis (IAC) with cholangiocarcinoma (CCA) [3, 6-12]

Characteristics		IAC	CCA
Older age		+++	+++
Male incidence		+++	++
Advanced symptoms, weight loss, etc.		+	+++
Indicative of bile duct obstruction	Obstructive jaundice	++	+++
Elevated liver enzymes and bilirubin		+	+++
Elevated alkaline phosphatase		+	++
Association with CCA		+/-	n/a
Associated with certain environmental factors	Parasitic hepatobiliary infections	-	+++
	Choledochal cyst, hepatolithiasis	-	+++
Other organ involvement	The pancreas, salivary glands, kidney, etc	+++	-
IBD		+++	-
Elevated serum levels of CA 19-9		+	-
Elevated serum IgG4		++	+++
Elevated bile IgG4 levels		+++	-
IgG4-positive cell infiltrates		+++	-
Response to steroids		+++	-

gical intervention. The key question of primary clinical importance is when to suspect IAC. For obvious reasons, a routine detection of IgG4 serum level in all patients with biliary strictures can not be recommended. Nevertheless, having in mind present clinical experience and information gathered on IAC so far, attention should be paid to the following: if ERCP is chosen as a diagnostic procedure, it is very important to insist on biopsy (forceps/brush) and obtaining an adequate tissue sample for analysis. This could be useful in revealing true nature of the disease. However, if some of the imaging techniques (MDCT, MRI/MRCP) are being performed, biliary strictures or pseudotumor formations are usually present. Regardless of what diagnostic procedure is being used, certain clinical features should always be taken into consideration. Other organ involvement (AIP, IBD, Sjögren's syndrome, retroperitoneal fibrosis) is highly suggestive for an autoimmune disorder. Moreover, clinical remissions and relapses of the disease are typical for an IAC and do not occur in patients with CCA. Even though diagnostic value of tumor markers is considered to be relatively low, they can be helpful in the exclusion of bile duct carcinoma. If all of the previously mentioned criteria are met, IgG4 serum level should be assessed. Values of more than 300 mg/dL are indicative of IAC. If so, patient should be treated conservatively with steroids, in the course of 11 weeks [3]. Azathioprine can be added to therapy for maintenance of remission, especially in proximal/intrahepatic strictures. Improvement in liver enzymes and biliary stricture resolution should be expected after 4–6 weeks [3]. Although HISORT criteria were a great contribution in diagnosing IAC, further clinical studies should be conducted on order to understand the disease better and develop new and more precise diagnostic procedures.

REFERENCES

1. Sarles H, Sarles JC, Muratore R, Guien C. Chronic inflammatory sclerosis of the pancreas – an autonomous pancreatic disease? *Am J Dig Dis.* 1961; 6:688-98.
2. Kamisawa T, Funata N, Hayashi Y, Koike M, Tsuruta K, et al. A new clinicopathological entity of IgG4-related autoimmune disease. *J Gastroenterol.* 2003; 38:982-4.
3. Ghazale A, Chari ST, Zhang L, Smyrk TC, Takahashi N, Levy MJ, et al. Immunoglobulin G4-associated cholangitis: clinical profile and response to therapy. *Gastroenterology.* 2008; 134:706-15.
4. Lytras D, Kalaitzakis E, Webster GJ, Imber CJ, Amin Z, Rodriguez-Justo M, et al. Cholangiocarcinoma or IgG4-associated cholangitis: how feasible it is to avoid unnecessary surgical interventions? *Ann Surg.* 2012; 256(6):1059-67.
5. Vosskuhl K, Negm AA, Framke T, Weismüller T, Manns MP, Wedemeyer H, et al. Measurement of IgG4 in bile: a new approach for the diagnosis of IgG4-associated cholangiopathy. *Endoscopy.* 2012; 44:48-52.
6. Kamisawa T, Okamoto A. Autoimmune pancreatitis: proposal of IgG4-related sclerosing disease. *J Gastroenterol.* 2006; 41:613-25.
7. Bambha K, Kim WR, Talwalkar J, Torgerson H, Benson JT, Therneau TM, et al. Incidence, clinical spectrum, and outcomes of primary sclerosing cholangitis in a United States community. *Gastroenterology.* 2003; 125:1364-9.
8. Karlsen TH, Schrumpf E, Boberg KM. Genetic epidemiology of primary sclerosing cholangitis. *World J Gastroenterol.* 2007; 13:5421-31.
9. Aron JH, Bowlus CL. The immunobiology of primary sclerosing cholangitis. *Semin Immunopathol.* 2009; 31:383-97.
10. Lazaridis KN, Gores GJ. Cholangiocarcinoma. *Gastroenterology.* 2005; 128:1655-67.
11. Li J, Zhao CC, Wang XM, Chen JH, Li XC, Shen YC. Hepatobiliary and pancreatic: autoimmune cholangitis, pancreatitis and sialadenitis. *J Gastroenterol Hepatol.* 2012; 27:988.
12. Nishino T, Oyama H, Hashimoto E, Toki F, Oi I, Kobayashi M, et al. Clinicopathological differentiation between sclerosing cholangitis with autoimmune pancreatitis and primary sclerosing cholangitis. *J Gastroenterol.* 2007; 42:550-9.

Приказ случаја аутоимунског холангитиса погрешно дијагностикованог као холангиокарцином: како избећи непотребну хируршку интервенцију?

Игор И. Игњатовић¹, Славко В. Матић^{1,2}, Владимир Д. Дугалић^{1,2}, Ђорђе М. Кнежевић^{1,2}, Марјан Т. Мицев^{2,3}, Марко Д. Богдановић¹, Србислав М. Кнежевић^{1,2}

¹Одељење за хепатобилијарну и хирургију панкреаса, Клиника за дигестивну хирургију – Прва хируршка клиника, Клинички центар Србије, Београд, Србија;

²Универзитет у Београду, Медицински факултет, Београд, Србија;

³Одељење за патологију, Клиника за дигестивну хирургију – Прва хируршка клиника, Клинички центар Србије, Београд, Србија

КРАТАК САДРЖАЈ

Увод Аутоимунски холангитис, односно холангитис удружен с имуноглобулином G4 (енгл. *IgG4-associated cholangitis – IAC*) онедавно се почео разматрати као нов клинички и хистопатолошки ентитет. Он је део сложеног аутоимунског поремећаја под називом „системска болест удружена са IgG4(+)“ (енгл. *IgG4-related systemic disease – ISD*). ISD је мултиорганско аутоимунско обољење које се одликује IgG4 плазмочитном инфилтрацијом различитих ткива и органа с последичном склерозом која добро реагује на лечење кортикостероидима. Најчешће захваћени органи су панкреас, у виду аутоимунског панкреатитиса, и главни жучни вод. Аутоимунски холангитис и холангиокарцином имају слична клиничка, лабораторијска и радиолошка обележја.

Приказ болесника Представљамо шездесетогодишњег мушкарца са билијарном стриктуром главног жучног во-

да која је протумачена као холангиокарцином, а болесник је подвргнут хируршком захвату. Коначна хистопатолошка анализа са додатним имунохистохемијским испитивањем показала је хронично запаљење са лимфоплазмочитном IgG(+) инфилтрацијом ресецираног дела главног жучног вода. Вредности IgG4 у серуму после операције биле су повишене.

Закључак Од клиничког је значаја направити разлику између аутоимунског холангитиса и холангиокарцинома, како би се избегла непотребна хируршка интервенција. Стога аутоимунски холангитис треба укључити у диференцијалну дијагнозу код свих случајева билијарних стриктура нејасне етиологије.

Кључне речи: аутоимунски холангитис; холангиокарцином; диференцијална дијагноза