

Achalasia – Two Types in the Same Patient: Case Report

Igor D. Jovanović¹, Dragana R. Jovanović², Milenko Uglješić², Nikola Milinić¹, Mirjana Cvetković¹, Marija Branković¹, Goran Nikolić¹

¹Clinical Hospital Center "Bežanijska kosa", Belgrade, Serbia;

²Clinical Center of Serbia, Belgrade, Serbia

SUMMARY

Introduction A paper presented a case of esophageal achalasia with both type 2 and type 3 achalasia found in the same patient.

Case Outline High resolution impedance manometry of esophagus was performed. Liquid swallows induced panesophageal pressurization (achalasia type 2), whereas viscous swallows led to compartmentalized pressurization – distal two thirds of esophagus (achalasia type 3). No complete bolus transit was recorded. Patient refused any procedure.

Conclusion The aim of this paper was to show the necessity of performing manometry using both liquid and viscous swallows in GI departments where this approach has not been routinely used in order to establish proper diagnosis since therapy approach is different between type 2 and type 3 achalasia.

Keywords: achalasia; bolus; esophagus; high resolution impedance manometry; transit

INTRODUCTION

The aim of this paper was to show the necessity of performing manometry using both liquid and viscous swallows in order to establish proper diagnosis. We would like to show that it is not rare having two types of achalasia in the same patient. Proper achalasia type and accordingly proper therapy approach could have been missed if both liquid and viscous swallows had not been used.

Sandhill Scientific Insight 3 GI diagnostic system with UNI –ESO –WG 1A1 manometric catheter was used.

Patient was placed in a standard supine position. Saline solution was used for liquid swallows and special Sandhill-made gel was used for viscous swallows.

CASE REPORT

A 76-year-old male patient presented to our hospital complaining of dysphagia for more than 15 years, with progressive dysphagia and weight loss of 10 kg in the last 6 months. He underwent cardiac surgery (aortic-coronary by-pass) in 2007, had a pulmonary embolism in 1964, and has been currently taking drugs for chronic bronchitis and arterial hypertension.

On physical examination, no abnormal findings were noted.

Laboratory test results showed normal MCV anemia with hemoglobin being 9.8 mg/l, the rest of values were within normal ranges.

Test results for renal and liver function were within normal limits. The upper gastrointestinal endoscopy revealed normal esophagus finding, with erosions seen in the antrum of

stomach. A barium-swallow study failed to show dilated esophagus, but rather narrowed distal two thirds of esophagus with tapering at the distal end (Figure 1).

High-resolution impedance manometry (HRIM) finding showed lower esophageal sphincter (LES) pressure at rest of 40 mm Hg with an average residual pressure of 28.6 mm Hg after liquid (wet) swallows and an average residual pressure of 21.4 mm Hg after viscous swallows. Therefore, LES manifested an impaired, incomplete relaxation.

Complete bolus transit was 0% in both liquid and viscous swallows.

Liquid swallows induced simultaneous contractions in the body of esophagus with so-called panesophageal pressurization – type 2 achalasia (Figure 2).

Nevertheless, viscous swallows induced segmental pressurization of distal two thirds of esophagus, which can be defined as type 3 achalasia (Figure 3).

Furthermore, 3D animation of esophagus during the viscous swallow showed simultaneous contraction in the distal two thirds of esophagus (Figure 3).

DISCUSSION

HRIM enables precise distinction between different types of achalasia [8]. There are the following types of achalasia: type 1 achalasia - with no distal pressurization (30 mm Hg, $\geq 8/10$ swallows), type 2 achalasia – with panesophageal pressurization to >30 mm Hg and type 3 achalasia with compartmentalized pressurization or spastic contractions with >2 swallows [1, 2, 3].

Correspondence to:

Igor D. JOVANOVIĆ
Clinical Hospital Center
"Bežanijska kosa"
Bežanijska kosa bb 11000
Belgrade
Serbia
igordusanov@yahoo.com

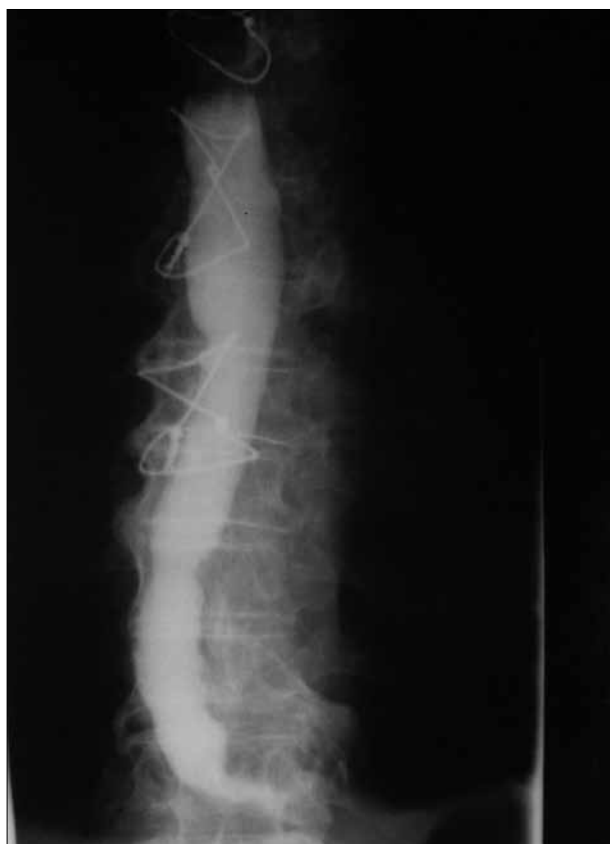

Figure 1. Barium enema study of esophagus showing narrowed esophageal distal two thirds and tapering at the distal end

Achalasia can be treated by drugs (nitrate, calcium channel blocker), endoscopically (botulinum toxin injection, balloon dilation, peroral endoscopic myotomy-POEM) and surgically (Heller's myotomy) [4, 7, 8]. There is a significant difference in therapy approach regarding achalasia type [10, 11]. Type 2 is a predictor of positive treatment response, whereas type 3 and pretreatment esophageal dilatation are predictive of negative treatment response [2, 3].

Furthermore, type 1 response to first intervention was 38% for dilation and 67% for Heller's myotomy [2, 9], type 2 – 73% and 100%, respectively, and in case of type 3 there was 0% of response for dilation and 0% of response for Heller's myotomy [2, 9].

Botulinum toxin injection showed response to first intervention of 0% for type 1, 86% for type 2 and 22% for type 3 of achalasia [2].

Therefore, Botox injection is recommended for type 3 achalasia [2, 5, 6]. A new procedure called POEM showed promising results in treating this type of achalasia [12]. POEM resembles Heller's myotomy, but since it is performed endoscopically, selective myotomy over a long distance is possible, vagus nerve injury is prevented, and an operation field is broader than with Heller's myotomy [12]. Nevertheless, given it is a new procedure it requires further evaluation by objective testing [12]. As a last possibility, esophageal resection with bowel interposition can be performed for type 3 achalasia. That is why we found a distinction between the achalasia types so important.

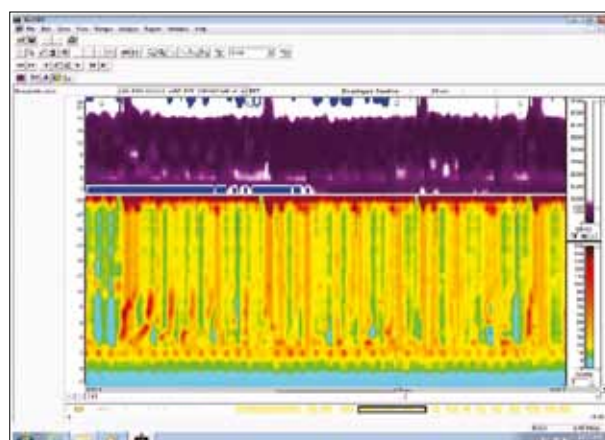


Figure 2. HRIM – "Close view" of type 2 achalasia with panesophageal pressurization

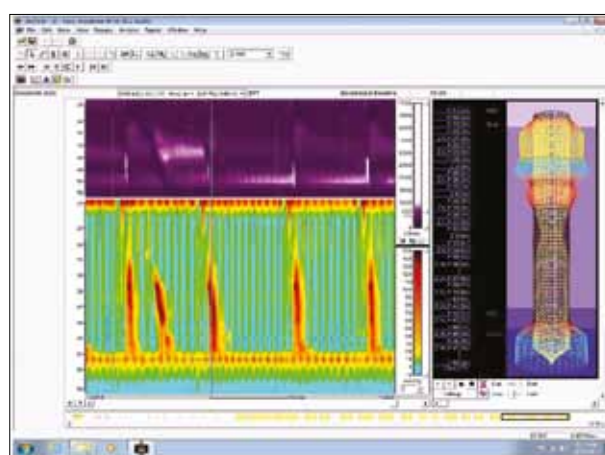


Figure 3. HRIM – "Close view" of type 3 achalasia with compartmentalized pressurization

Our patient showed signs of achalasia: simultaneous contractions in esophageal body and incomplete LES relaxation. Liquid swallows induced esophageal pan-pressurization (achalasia-type 2, Figure 2), whereas viscous swallows induced compartmentalized pressurization of esophagus (achalasia-type 3, Figure 3).

Having in mind the fact that the patient has had swallowing difficulties for 15 years, esophageal barium enema study without the signs of prestenotic dilatation, but rather narrowing, goes along with type 3 achalasia.

Type 2 achalasia can be treated by balloon dilation or Heller's myotomy.

Type 3 achalasia requires different operating procedures (Botox injection rather than dilation or Heller's myotomy, POEM, esophageal resection with bowel interposition as a last possibility) [2].

Having in mind patient's weight loss during the past six months, we decided to define it as type 3 achalasia.

At this moment patient refuses any kind of procedure including nutritive gastrostomy.

Based on the possibility of more than one type of achalasia in the same patient, we strongly recommend HRIM using both liquid and viscous swallows in GI departments where this approach is not routinely used in order to come to the right diagnosis and appropriate treatment strategy.

REFERENCES

- Hong SJ, Bhargava V, Jiang Y, DeBoer D, Mittal RK. A unique esophageal motor pattern that involves longitudinal muscles is responsible for emptying in achalasia esophagus. *Gastroenterology*. 2010; 139:102-11.
- Pandolfino JE, Keiatak MA, Nealis T, Bulsiewicz W, Post J, Kahrilas PJ. Achalasia: a new clinically relevant classification by high-resolution manometry. *Gastroenterology*. 2008; 135:1526-33.
- Richter JE. Achalasia – an update. *J Neurogastroenterol Motil*. 2010; 16(3):232-42.
- Richter JE. Oesophageal motility disorders. *Lancet*. 2001; 358:823-8.
- Rohof WO, Salvador R, Annese V, Bruley des Varannes S, Chaussade S, Costantini M, et al. Outcomes of treatment for achalasia depend on manometric subtype. *Gastroenterology*. 2013; 144(4):718-25.
- Pratap N, Kalapala R, Darisetty S, Joshi N, Ramchandani M, Banerjee R, et al. Achalasia cardia subtyping by high-resolution manometry predicts the therapeutic outcome of pneumatic balloon dilatation. *J Neurogastroenterol Motil*. 2011; 17:48-53.
- Salvador R, Costantini M, Zaninotto G, Morbin T, Rizzetto C, Zanatta L, et al. The preoperative manometric pattern predicts the outcome of surgical treatment for esophageal achalasia. *J Gastrointest Surg*. 2010; 14:1635-45.
- Bansal A, Kahrilas PJ. Has high-resolution manometry changed the approach to esophageal motility disorders? *Curr Opin Gastroenterol*. 2010; 26:344-51.
- Aldersliesten J, Concilio JM, Leeuwenburgh I, Steyerberg EW, Kuipers EJ. Predictors of failure of balloon dilatation in patients with achalasia. *Gut*. 2011; 60:10-6.
- Francis DL, Katzka DA. Achalasia: update on the disease and its treatment. *Gastroenterology*. 2010; 139:369-74.
- Kushnir V, Sayuk GS, Gyawali CP. Multiple rapid swallow responses segregate achalasia subtypes on high-resolution manometry. *Neurogastroenterol Motil*. 2012; 24(12):1069-e561.
- Lee BH, Shim KY, Hong SJ, Bok GH, Cho JH, Lee TH, et al. Peroral endoscopic myotomy for treatment of achalasia: initial results of a Korean study. *Clin Endosc*. 2013; 46(2):161-7.

Ахалазија – два типа код истог болесника

Игор Д. Јовановић¹, Драгана Р. Јовановић², Миленко Угљеша², Никола Милинић¹, Мирјана Цветковић¹, Марија Бранковић¹, Горан Николић¹

¹Клиничко-болнички центар „Бежанијска коса“, Београд, Србија;

²Клинички центар Србије, Београд, Србија

КРАТАК САДРЖАЈ

Увод У раду је приказан случај ахалазије тип 2 и тип 3, који су дијагностиковани код истог болесника.

Приказ болесника Болеснику је урађена високорезолуцијска манометрија једњака. Течни гутљаји су изазвали панезофагеалну пресуризацију (ахалазија тип 2), док су вискозни гутљаји изазвали слику сегментне пресуризације – дисталне две трећине једњака (ахалазија тип 3). Није забележен ни-

један комплетан транзит болуса. Болесник је одбио било какво лечење.

Закључак Циљ овог приказа био је да покаже неопходност извођења манометрије једњака са течним и вискозним гутљајима у центрима где се овакав начин процене стања једњака не примењује, јер је терапијски приступ различит у односу на тип ахалазије.

Кључне речи: ахалазија; болус; једњак; манометрија; транзит

Примљен • Received: 03/09/2012

Ревизија • Revision: 19/09/2013

Прихваћен • Accepted: 22/10/2013