

Primary Merkel Cell Carcinoma of the Eyelid – Clinical, Histopathological, Immunohistochemical and Electron Microscopical Features: A Case Report

Anica Bobić Radovanović^{1,2}, Zoran Latković^{1,2,3}, Milica Labudović Borović^{1,4}, Dejan M. Rašić^{1,2,3}

¹University of Belgrade, School of Medicine, Belgrade, Serbia;

²Clinic of Eye Diseases, Clinical Center of Serbia, Belgrade, Serbia;

³Ophthalmic Pathology Laboratory, Clinic of Eye Diseases, Clinical Center of Serbia, Belgrade, Serbia;

⁴University of Belgrade, School of Medicine, Institute of Histology and Embryology – Electron Microscopy Department, Belgrade, Serbia

SUMMARY

Introduction Merkel cell carcinoma (MCC) is a rare eyelid neoplasm which can cause significant diagnostic and especially therapeutic challenges.

Case Outline This is the first documented report of the case of primary MCC of the eyelid in Serbia.

Conclusion The optimal therapy must be individualized in any given patient and, early diagnosis and meticulous follow-up are mandatory to achieve a long-term cure.

Keywords: Merkel cell carcinoma; eyelid; histopathology; immunohistochemistry; electron microscopy

INTRODUCTION

Merkel cell carcinoma (MCC) is a rare eyelid primary neoplasm. It is predominantly found among elderly Caucasian adults aged 47 to 95 years, with female patients twice as predominant. The known or probable risk factors include sun exposure, immune suppression and viral infection. As one of the most aggressive/highly malignant cutaneous cancer, eyelid MCC can cause significant diagnostic (clinical as well as histopathological) and especially therapeutic challenges [1-30].

CASE REPORT

Clinical history

A 72-year-old woman was referred to the University Hospital, Clinic of Eye Diseases, Clinical Centre of Serbia, in 2009. A painless, progressively enlarging growth on her left upper eyelid started several months earlier. The tumor was violaceous, purple-reddish in color, solid, protuberant, partly nodular, approximately 25×15 mm, involving the temporal part of the left upper eyelid, with telangiectatic blood vessels at the surface and some loss of cilia (Figure 1A). She did not experience any ocular pain or visual disturbance. Anterior and posterior segments of both eyes were otherwise unremarkable with only incipient age-related changes. Neither the ipsilateral preauricular nor the ipsilateral submandibular lymph nodes were enlarged on palpation. The patient was otherwise healthy according to her age. The initial clinical impression was a malignant eye-

lid neoplasm. First, an incisional biopsy was made and it was suggestive of MCC, based on histologic features (densely packed small hyperchromatic cells with scant cytoplasm) and immunohistochemical phenotype (CK AE1/AE3 and CK20 showed a characteristic punctate perinuclear dot-like staining pattern of reactivity with strong intensity; NSE, synaptophysin, chromogranin A, PGP 9.5 and CD44 were also positive, and CK7, TTF-1, neurofilament, CEA, S100, HMB-45, LCA and vimentin were negative) (Figure 2).

One week later, under general anesthesia, an excisional biopsy was performed, when almost entire upper eyelid was removed and repaired with subsequent reconstruction. No operative or postoperative complications were noted. Also, a systemic work-up – echography of the abdomen and chest radiography – excluded distant metastases. No adjuvant prophylactic irradiation of the tissues between the tumor and first regional lymphatic nodes was performed. Six years after surgery (Figure 1C), the patient has been well and without any signs of local recurrence, regional lymph node involvement or metastatic disease – regular follow-ups are scheduled in every three to six months.

Ophthalmic pathology findings

Gross examination of the excisional biopsy specimen showed a well-circumscribed, whitish-yellowish tan mass measuring 21×10–11×3–5 mm (Figure 1B). On cut surface, the lesion was whitish and sharply circumscribed. Very few small hemorrhages were evident throughout the lesion (Figure 1B inset).

Correspondence to:

Dejan M. RAŠIĆ
Clinic of Eye Diseases
Clinical Center of Serbia
Pasterova 2, 11000 Belgrade
Serbia
drnased@gmail.com

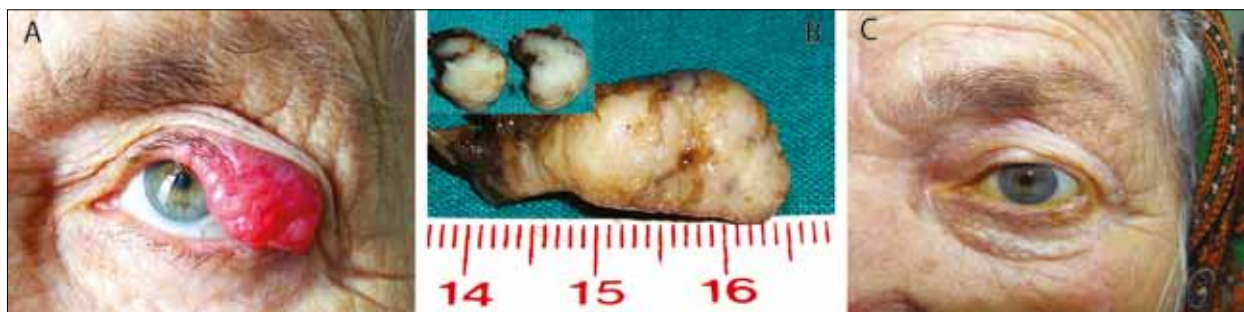

Figure 1. **A.** Purple-reddish, solid, protuberant, partly nodular lesion, with telangiectatic blood vessels at the surface and some loss of cilia, causing mechanical blepharoptosis; ulcerated periphery of the lesion is from previous incisional biopsy. **B.** Excisional biopsy specimen. On cut surface, lesion is whitish and sharply circumscribed with just a few small hemorrhages evident throughout (inset). **C.** Five years after surgery there are no signs of local recurrence with satisfactory functional and cosmetic appearance.

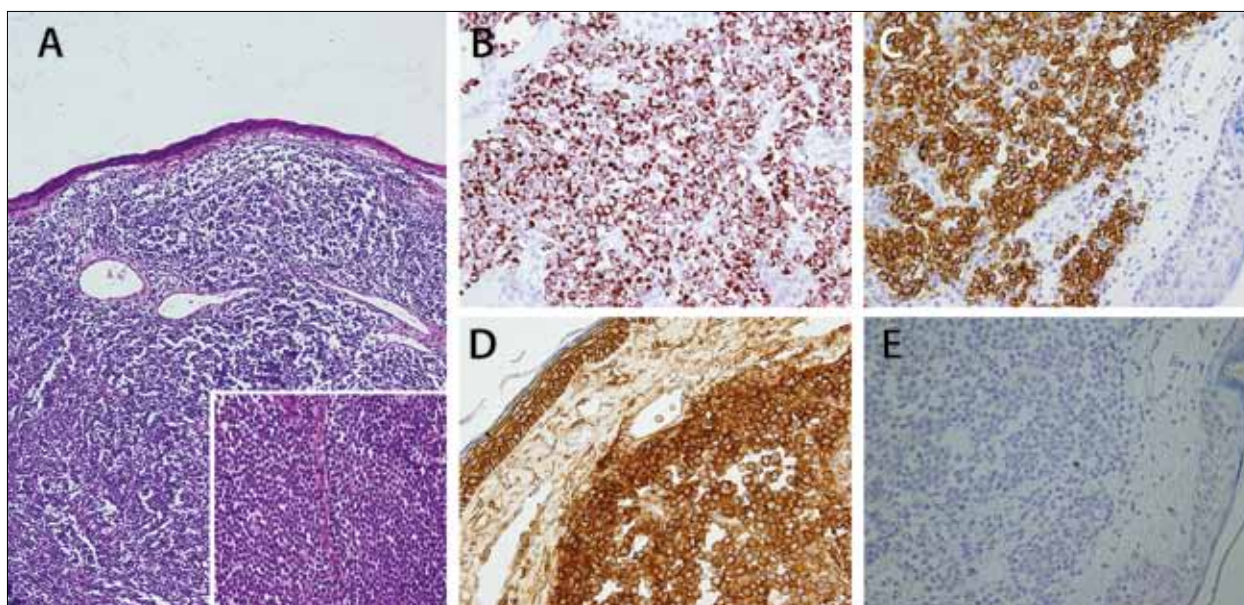


Figure 2. **A.** Tumor is confined within the dermis, with a tumor-free subepidermal "grenz" zone (HE, $\times 100$). Densely packed small hyperchromatic cells with scant cytoplasm, smoothly contoured round to oval pale nuclei with small nucleoli; relatively numerous mitotic figures and apoptotic bodies are present (HE, $\times 400$) (inset). **B.** CK20 showing strong punctate perinuclear dot-like expression ($\times 400$). **C.** Synaptophysin showing strong perinuclear cytoplasmic positivity ($\times 400$). **D.** CD44 showing strong perinuclear cytoplasmic positivity ($\times 400$). **E.** TTF-1 is negative ($\times 400$).

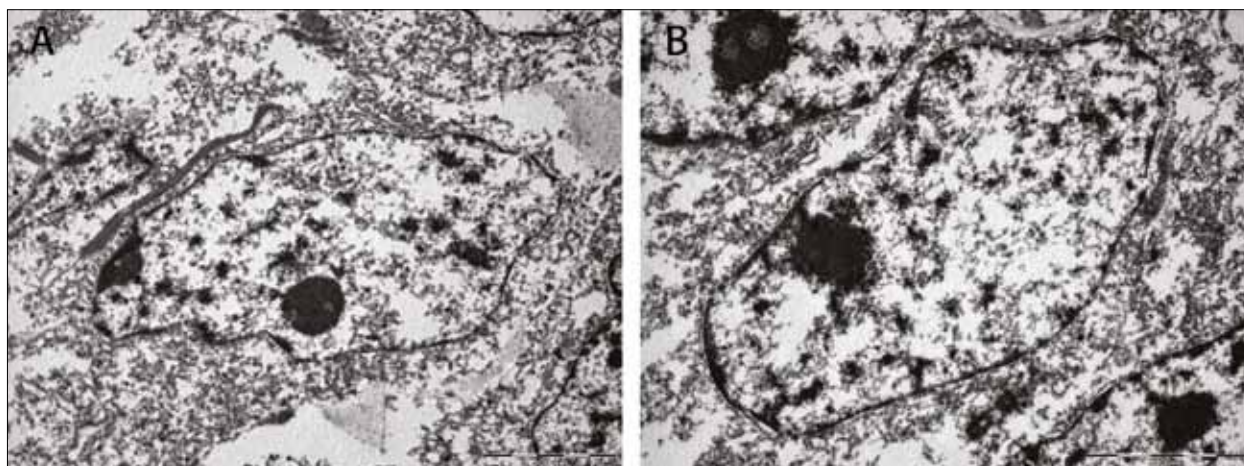


Figure 3. **A.** Transmission electron microscopy showing polygonal tumor cells with indented nuclei and small nucleoli with paranuclear aggregates of intermediate filaments and fibrous bodies and cytoplasmic small clear vesicle (7.1 k). **B.** TEM showing very few cytoplasmic dense core granules (8.9 k).

Light microscopy examination of excisional biopsy specimen revealed the following (Figure 3): The tumor was confined within the dermis, with a tumor-free subepidermal “grenz” zone (the so-called band of Unna). Neoplasm was composed of densely packed small hyperchromatic cells with sparse cytoplasm, smoothly contoured round to oval pale nuclei, finely dispersed/granular (“salt and pepper”) chromatin pattern and small nucleoli. The tumor grew in an intermediate cell type pattern, consisting of solid nests with trabeculae at the periphery and of diffusely infiltrative lymphoma-like appearance. Mitotic activity was brisk/abundant, 4 to 8 mitoses per 1 high-power field ($\times 400$). Apoptotic bodies were also identified. A non-brisk lymphocytic infiltrate surrounded and infiltrated the tumor. We were not able to identify unequivocal vascular or lymphatic invasion because of the density of tumor infiltration and because of a retraction phenomenon/clefting artifacts that surrounds groups of tumor cells. Surgical resection line was free of tumor cells.

On transmission electron microscopy examination (Figure 3) the tumor cells were polygonal in shape, often with indented nuclei and multiple small nucleoli. We found very few cytoplasmic dense core granules (most of the granules were destroyed during preparation of the tissue for transmission electron microscopy from formalin-fixed deparaffinized tissue) and very few small clear vesicles, but we managed to confirm the presence of paranuclear aggregates of intermediate filaments and fibrous bodies.

Our final diagnosis was consistent with primary MCC of the eyelid, pT2c (II B).

DISCUSSION

MCC is a rare primary malignant neoplasm of the skin. Eyelids are affected in approximately 5–10% of all MCC cases, making MCC an ophthalmologic entity as well. Until now, some 90 MCCs of the eyelid have been reported in the literature [1-30]. Also, primary MCC can be found in periocular region such as conjunctiva [17], lacrimal gland [18] and eyebrow [19], or as a metastatic deposit in the uvea (iris [20], ciliary body [21] and choroid [22]). Spontaneous regression [23] and orbital invasiveness [19, 24, 29] of primary eyelid MCC have been also described.

MCC of the eyelid has a substantial rate of local recurrence (about one third of these tumors, usually within 1 year) and presence of metastatic spread in a significant percentage of cases. Almost two thirds of the eyelid MCC cases give rise to regional lymph node metastases, mostly within 18 months, and up to a half metastasize systemically, most frequently within 2 years, resulting in death. Overall, only about 50% of eyelid MCC cases have a localized disease at diagnosis [1-30].

Clinically, MCC of the eyelid is a solitary, painless, nontender, often protuberant, bulging, characteristically reddish in color dome-shaped nodule, whose surface is smooth, frequently shiny, sometimes nodular, very often with telangiectatic blood vessels, usually with intact over-

lying epidermis, and located near the lid margin, often causing partial loss of the eyelashes, with relatively rapid growth [1-30]. Some of the eyelid MCCs have been pedunculated [2, 13], mimicking chalazia [25], giant in size [26], bilateral [27], synchronous in appearance on both ipsilateral eyelids [28], cystic [7], associated/synchronous co-existent with sebaceous gland carcinoma [30], etc.

On light microscopy, three histopathologic patterns exist (not influenced in prognosis): trabecular ($\geq 75\%$ of tumor mass), diffuse (small cell; $\geq 75\%$ of tumor mass), and intermediate (trabecular and diffuse; trabecular pattern comprises $\geq 25\%$ but $< 75\%$ of tumor mass), with intermediate being the most common [1, 5, 6, 9, 11]. Tumor size, invasion into tarsal plate tissue, diffuse growth pattern, heavy tumor lymphocytic infiltration (comprise $> 2/3$ of tumor mass), angiolymphatic invasion, high tumor vascular density, increased number of mast cells throughout the tumor, mitotic index greater than 5 mitoses per high-power field were all associated with poor outcome [1, 5, 6, 9, 11, 23]. Eccrine, squamous and leiomyosarcomatous differentiation has also been reported [1, 11], as well as epidermotropism. Vascular invasion is an early event in pathogenesis of MCC [12, 23]. Additional morphological features or divergent types of differentiation, sometimes observed in MCC are: epidermotropism, aggregates of tumor cells at the dermal-epidermal junction, aggregates of tumor cells producing a pseudorosette appearance, aggregates of giant or bizarre tumor cells, squamous, eccrine, leiomyomatous, or melanocytic differentiation, entrapment of sweat ducts or glands by tumor cells, tumor cells within arrector pili muscle, molding of cells as a ball-in-mitt arrangement, Azzopardi phenomenon, overlying changes or other malignant neoplasms/collision lesions within or adjacent to / co-existent with MCC such as Bowen disease, actinic keratosis, invasive squamous cell carcinoma, basal cell carcinoma, sebaceous gland carcinoma or sweat gland tumors [1, 5, 6, 9, 11, 12].

Immunohistochemical findings in MCC [1-30] are unique in that they possess both epithelial and neuroendocrine features. Pan-cytokeratin AE1/AE3, EMA, CAM 5.2, and Ber-EP4 are expressed by malignant MCC cells. The very most of reported eyelid MCCs have been CK20 positive in a dot-like perinuclear pattern, and CK7 negative. A wide range of neuroendocrine markers such as neurofilaments, NSE, chromogranin, synaptophysin, bombesin, somatostatin, VIP, PGP 9.5 and proconvertases PC1/PC3 and PC2.7 are expressed by MCC cells. Also, MCC may express CD9, CD37, CD44 (expression with possible but not yet universally accepted connection with an increased risk of metastasis), CD56, CD63, CD117, CD151, rarely CD99 and TdT; however, it is negative for TTF-1 (differentiating between metastatic small cell carcinoma of the lung which stains positively), neurofilament (differentiating between metastatic SCCL which stains negatively), S100 and HMB-45 (differentiating between melanoma which stains positively), and LCA and vimentin (differentiating between lymphoma which stains positively).

In differential diagnosis [1-30], clinical as well as histopathological, among malignant neoplasms, eyelid lym-

phoma and leukemic infiltrate, metastatic eyelid tumors (especially small cell carcinoma of the lung, neuroblastoma or carcinoid), and amelanotic cutaneous melanoma are the three most common entities to exclude. Also, other primary eyelid cancers such as basal cell carcinoma, sebaceous gland carcinoma, squamous cell carcinoma, sweat gland carcinoma or rhabdomyosarcoma should be considered as well. Among tumor-like and benign neoplasms, the most common entities to be excluded are vascular lesions, adnexal tumors, cysts, pyogenic granuloma and chalazion.

As it can be expected, there is no single standard for eyelid MCC treatment yet [1-30], comparing with treatment modalities of MCC elsewhere. Existing recommendations are a result of individual experience on different series of patients. The optimal therapy must be tailored for any given patient. When a diagnosis of MCC is established, it is necessary to find out a stage of the disease. During the past 20 years, five different staging systems have been proposed for MCC, which results in confusion and inconsistency. Practically, there are three stages of the disease: localized skin disease, regional lymph node disease and metastatic disease. Unfortunately, the percentage of patients in advanced stages of the disease at a time of the diagnosis is high, between one fourth and more than a half. Chest radiography, serologic evaluation of liver function and complete blood count for each patient with established diagnosis of localized eyelid MCC are suggested. If there is any abnormality on this evaluation, further investigations are, of course, necessary.

The current primary treatment of the MCC of the eyelid [1-30] consists of excision with at least 3 mm margins, with histopathologic confirmation of tumor-free resection lines. Frozen section assessment, including Mohs surgery, is appropriate. Adjuvant prophylactic irradiation of the tissues between the tumor and first regional lymphatic nodes (50–60 Gy in 20–25 fractions) is generally recommended (except for patients who have small tumors and no evidence of lymphatic or lymph node involvement), because the MCC is a neoplasm highly sensitive to ionizing radiation therapy. Postoperative radiotherapy for tumor site and regional lymph nodes has significant importance for local control of the disease, but no impact on the incidence of metastatic disease and survival rate.

In conclusion, early diagnosis, staging and adequate first-line therapy consisting of surgical treatment with wide local resection of the primary lesion with tumor-free margins are the most important therapeutic steps. If needed, prophylactic radiotherapy can be an adjuvant treatment – radiation of the tumor site, and of the regional lymph nodes area. Local recurrence is treated in the same way. Sentinel lymph node mapping is a procedure for recognizing micrometastasis in regional lymph nodes. Regional lymph node disease is treated by operation (lymph node dissection) and radiotherapy and, in selected cases, by adjuvant chemotherapy. Chemotherapy, a palliative therapeutic option for patients with metastatic disease, is similar to that used for patients with small cell carcinoma of the lung. Meticulous follow-up often involving multidisciplinary team is mandatory to achieve a long-term cure.

REFERENCES

- Kivelä T, Tarkkanen A. The Merkel cell and associated neoplasms in the eyelids and periocular region. *Surv Ophthalmol.* 1990; 35(3):171-87.
- Kirkham N, Cole MD. Merkel cell carcinoma: a malignant neuroendocrine tumor of the eyelid. *Br J Ophthalmol.* 1983; 67(9):600-3.
- Lamping K, Fischer MJ, Vareska G, Levine MR, Aikawa M, Albert DM. A Merkel cell tumor of the eyelid. *Ophthalmology.* 1983; 90(12):1399-402.
- Proença R, Santos MF, Cunha-Vaz JG. Primary neuroendocrine carcinoma of the eyelid, immunohistochemical and ultrastructural study. *Int Ophthalmol.* 1990; 14(4):251-8.
- Rubsamen PE, Tanenbaum M, Grove AS, Gould E. Merkel cell carcinoma of the eyelid and periocular tissues. *Am J Ophthalmol.* 1992; 113(6):674-80.
- Singh AD, Eagle RC Jr, Shields CL, Shields JA. Merkel cell carcinoma of the eyelids. *Int Ophthalmol Clin* 1993; 33(3):11-7.
- Soltau JB, Smith ME, Custer PL. Merkel cell carcinoma of the eyelid. *Am J Ophthalmol.* 1996; 121(3):331-2.
- Li S, Brownstein S, Addison DJ, Klintworth GK, Jordan DR, Codère F. Merkel cell carcinoma of the eyelid. *Can J Ophthalmol.* 1997; 32(7):455-61.
- Metz KA, Jacob M, Schmidt U, Steuhl KP, Leder LD. Merkel cell carcinoma of the eyelid: histological and immunohistochemical features with special respect to differential diagnosis. *Graefes Arch Clin Exp Ophthalmol.* 1998; 236(8):561-6.
- Collaço L, Silva JP, Gonçalves M, Abrantes P. Merkel cell carcinoma of the eyelid: a case report. *Eur J Ophthalmol.* 2000; 10(2):173-6.
- Colombo F, Holbach LM, Jünemann AG, Schlötzer-Schrehardt U, Naumann GO. Merkel cell carcinoma: clinicopathologic correlation, management, and follow-up in five patients. *Ophthalm Plast Reconstr Surg.* 2000; 16(6):453-8.
- Peters GB 3rd, Meyer DR, Shields JA, Custer PL, Rubin PA, Wojno TH, et al. Management and prognosis of Merkel cell carcinoma of the eyelid. *Ophthalmology.* 2001; 108(9):1575-9.
- Esmaili B, Naderi A, Hidaji L, Blumenschein G, Prieto VG. Merkel cell carcinoma of the eyelid with a positive sentinel node. *Arch Ophthalmol.* 2002; 120(5):646-8.
- Nicoletti AG, Matayoshi S, Santo RM, Ferreira VR. Eyelid Merkel cell carcinoma: report of three cases. *Ophthalm Plast Reconstr Surg.* 2004; 20(2):117-21.
- Usui Y, Rao NA. Merkel cell carcinoma of the eyelid: report of a case with immunohistochemical study. *Jpn J Ophthalmol.* 2004; 48(3):306-8.
- Saedon H, Hubbard A. An unusual presentation of Merkel cell carcinoma of the eyelid. *Orbit.* 2008; 27(4):331-3.
- Kase S, Ishijima K, Ishida S, Rao NA. Merkel cell carcinoma of the conjunctiva. *Ophthalmology.* 2010; 117(3):637.e1-2.
- Gess AJ, Silkiss RZ. A Merkel cell carcinoma of the lacrimal gland. *Ophthalm Plast Reconstr Surg.* 2012; 28(1):e11-3.
- Seiberth V, Woldt C. Merkel cell carcinoma of the eyebrow extending into the orbit. *Eur J Ophthalmol.* 2000; 10(4):330-1.
- Kirwan C, Carney D, O'Keefe M. Merkel cell carcinoma metastasis to the iris in a 23-year-old female. *Ir Med J.* 2009; 102(2):53-4.
- Purgason PA, Hornbliss A, Harrison W. Metastatic Merkel cell carcinoma to the eye. *Ophthalmology.* 1991; 98(9):1432-4.
- Trichopoulos N, Augsburg JJ. Neuroendocrine tumors metastatic to the uvea: diagnosis by fine needle aspiration biopsy. *Graefes Arch Clin Exp Ophthalmol.* 2006; 244(4):524-8.
- Missotten GS, de Wolff-Rouendaal D, de Keizer RJ. Merkel cell carcinoma of the eyelid: review of the literature and report of patients with Merkel cell carcinoma showing spontaneous regression. *Ophthalmology.* 2008; 115(1):195-201.

24. Offret H, Badarani N, Quillard J, Bloch-Michel E. Orbital invasiveness of Merkel cell tumor of the eyelid. *J Fr Ophthalmol.* 1992; 15(11):605-9.
25. Rawlings NG, Brownstein S, Jordan DR. Merkel cell carcinoma masquerading as a chalazion. *Can J Ophthalmol.* 2007; 42(3):469-70.
26. Chen L, Zhu L, Wu J, Lin T, Sun B, He Y. Giant Merkel cell carcinoma of the eyelid: a case report and review of the literature. *World J Surg Oncol.* 2011; 9:58.
27. Thakur S, Chalioulas K, Hayes M, While A. Bilateral primary Merkel cell carcinoma of the upper lid misdiagnosed as basal cell carcinoma. *Orbit.* 2008; 27(2):139-41.
28. Marshmann WE, McNab AA. Merkel cell tumor occurring simultaneously in the upper and lower eyelids. *Aust N Z J Ophthalmol.* 1996; 24(4):377-80.
29. Yildirim S, Aköz T, Yavuzer D, Akan M, Avci G. A case of Merkel cell carcinoma with extension into the orbital cavity [letter]. *Ann Plast Surg.* 2001; 46(2):198-9.
30. Tanahashi J, Kashima K, Daa T, Yada N, Fujiwara S, Yokoyama S. Merkel cell carcinoma co-existent with sebaceous carcinoma of the eyelid. *J Cutan Pathol.* 2008; 36(9):983-6.

Примарни карцином Меркелових ћелија капка – клиничке, хистопатолошке, имунохистохемијске и електронскомикроскопске одлике: приказ болесника

Аница Бобић Радовановић^{1,2}, Зоран Латковић^{1,2,3}, Милица Лабудовић Боровић^{1,4}, Дејан М. Рашић^{1,2,3}

¹Универзитет у Београду, Медицински факултет, Београд, Србија;

²Клиника за очне болести, Клинички центар Србије, Београд, Србија;

³Офталмопатолошка лабораторија Клинике за очне болести, Клинички центар Србије, Београд, Србија;

⁴Универзитет у Београду, Медицински факултет, Институт за хистологију и ембриологију – Одсек за електронску микроскопију, Београд, Србија

КРАТАК САДРЖАЈ

Увод Карцином Меркелових ћелија (КМЋ) је веома редак малигни тумор коже капка. Диференцијалнодијагностички и терапијски представља изазов.

Приказ болесника Ово је први документовани случај примарног КМЋ капка у Србији.

Закључак Када се постави дијагноза, неопходно је применити оптималну терапију прилагођену сваком болеснику понаособ, што је уз пажљиво клиничко праћење болесника услов да се постигне излечење или дуже преживљавање.

Кључне речи: карцином Меркелових ћелија; капак; хистопатологија; имунохистохемија; електронска микроскопија

Примљен • Received: 05/05/2014

Прихваћен • Accepted: 10/03/2015