



ORIGINAL ARTICLE / ОРИГИНАЛНИ РАД

Clinical features of non-classical celiac disease in children and adolescents

Nedeljko Radlović¹, Zoran Leković^{2,3}, Vladimir Radlović^{2,3}, Jelena Mandić⁴, Marija Mladenović⁵, Jelena Radlović⁶, Biljana Vuletić^{7,8}, Siniša Dučić^{2,3}, Bojan Bukva^{2,3}, Ivana Dašić²

¹Academy of Medical Sciences of the Serbian Medical Society, Belgrade, Serbia;

²University Children's Hospital, Belgrade, Serbia;

³University of Belgrade, Faculty of Medicine, Belgrade, Serbia;

⁴University of Belgrade, School of Dental Medicine, Clinic for Pediatric and Preventive Dentistry, Belgrade, Serbia;

⁵Singidunum University, Faculty of Health, Legal and Business Studies, Valjevo, Serbia;

⁶Railways of Serbia Institute for Health Care of Workers, Belgrade, Serbia;

⁷Pediatric Clinic of the Clinical Center Kragujevac, Kragujevac, Serbia;

⁸University of Kragujevac, Faculty of Medical Sciences, Kragujevac, Serbia

SUMMARY

Introduction/Objective Nonclassical celiac disease (CD) is characterized by a very heterogeneous and non-specific clinical presentation.

The aim of this study was to determine the basic symptoms and clinical signs of this CD subtype in children and adolescents

Methods The study was based on a sample of 58 children and adolescent, 38 female and 20 male, ages 1.75 to 17.75 (10.01 ± 4.62) years with a nonclassical CD diagnosed according to the European Society for Pediatric Gastroenterology, Hepatology and Nutrition criteria from 1990 and 2012.

Results Except four patients who were between the ages of 1.75 to 2.50 years, all others were older than three years. The main clinical symptoms and signs suggestive of non-classical CD were anemia caused by iron deficiency (48.28%), short stature (34.48%), and intermittent abdominal pain (18.97%), anorexia with stagnation or weight loss (13.79%), and chronic constipation (6.9%). Thirty patients had one symptom or sign of the disease, 15 had two and 13 had three. In addition, 12 patients had dental enamel hypoplasia, 18 sideropenia without anemia and five mild isolated hypertransaminasemia. A gluten-free diet, apart from the dental enamel hypoplasia, has resulted in the withdrawal of all indicators of the disease.

Conclusion The main symptoms and clinical signs of nonclassical CD in children and adolescents were iron deficiency anemia, short stature and intermittent abdominal pain, and less frequently anorexia with stagnation or weight loss and chronic constipation. Excluding dental enamel hypoplasia, a gluten-free diet leads to a complete recovery of the patient.

Keywords: nonclassical celiac disease; children and adolescents; symptoms and signs

INTRODUCTION

Celiac disease (CD) is one of the most frequent autoimmune diseases of the modern man [1, 2, 3]. It primarily occurs in white population (~1%) as a result of polygenic predisposition and exposure to gluten and related prolamins of wheat, rye, and barley [1, 4, 5, 6]. The basis of the disease and the key finding in its diagnostics is gluten-sensitive enteropathy, i.e., a non-specific inflammation of the small intestinal mucosa that resolves by gluten-free diet [6–9]. Beside enteropathy, either symptomatic or asymptomatic, the disease is also characterized by different extraintestinal manifestations [8–11]. From the clinical aspect, CD is divided into two basic types: symptomatic and asymptomatic [10]. Symptomatic disease is further differentiated to classical (typical) and non-classical (atypical) [8, 9, 10]. Classical CD is characterized by poor appetite, chronic diarrhea, failure to thrive, muscle wasting, abdominal distension and irritability, while non-classical forms of the

disease are dominated by atypical digestive and/or various extraintestinal manifestations, such as constipation, abdominal pain episodes, isolated hypertransaminasemia, aphthous stomatitis, iron deficiency anemia, short stature, delayed puberty, decreased bone density (osteopenia or osteoporosis), alopecia, chronic fatigue, anxiety, depression, and others [10–16]. The classic CD form is most often seen at the age of 9–36 months and non-classical in later childhood, adolescence and in adulthood [8, 17].

The aim of our study was to analyze the symptoms and clinical signs of non-classical CD in children and adolescents. In addition, the degree of damage to the small intestinal mucosa obtained by enterobiopsy in this CD subtypes was also considered.

METHODS

The objectives of the study were considered on a sample of 58 children (38 female; with age

Received • Примљено:
June 26, 2020

Revised • Ревизија:
September 2, 2020

Accepted • Прихваћено:
September 8, 2020

Online first: September 11, 2020

Correspondence to:

Nedeljko RADLOVIĆ
Serbian Medical Association
Džordža Vašingtona 19
110000 Belgrade
Serbia
n.radlovic@beotel.net

range 1.75–17.75 years, mean 10.01 ± 4.62 years) nonclassical CD confirmed in two of the five reference centers in Serbia during the period from January 1994 to December 2019. The study protocol was approved by the local Committees on Ethics. The diagnosis of CD was based on the revised criteria of the European Society for Pediatric Gastroenterology, Hepatology and Nutrition (ESPGHAN) from 1989 and on the new ESPGHAN guidelines published in 2012 [9, 18]. The Oslo definitions for CD were used for differentiation of non-classical and classical type of the disease [10].

In each patient's anamnesis, the exact data related to the onset, duration and type of symptoms on the clinical signs of the underlying disease are required, while in the context of the complete clinical examination each of them accurately measured body length/height and weight and the obtained values compared to the standard for the appropriate age and gender [19]. The values of body length/height are expressed in percentages, and deviations in body weight in relation to the ideal in percent. Additionally, in all patients with short stature, in order to evaluate the maturity of the bone, the x-ray of the left hand "en face" was performed. The used reference standard for determining bone age was the Greulich and Pyle Atlas [20].

Blood count, serum iron and ferritin concentrations and other laboratory nutritional indicators (total proteins, albumin, urea, total cholesterol, 3-glyceride, calcium, phosphorus and alkaline phosphatase), as well as the liver function test (bilirubinemia, total and conjugated, ALT, AST and gamma-glutamyl transferase) were determined by standard laboratory methods from a blood portion taken in the morning and before breakfast. The obtained findings are compared with standard reference values [21]. The diagnostic criterion for anemia was level of the hemoglobin (Hb) for children up to the age of five below 110 g/l for those 5–11 years below 115 g/l and for those over 11 years of 120 g/l [22]. The Hb value of 100–109 g/l was classified as a mild anemia, 70–99 g/l moderate, and below 70 g/l severe [22]. The reference value for the iron serum concentration was 10.7–31.3 $\mu\text{mol/l}$ [21]. In patients with hypertransaminasemia, the serum creatine phosphokinase activity was determined, so any of them, in addition to the absence of cholestas and hemolysis, had no elements for rhabdomyolysis. In addition, none received any of the medications followed by an increase in the serum level of transaminases, nor did it have an intercurrent infection that would produce this effect.

In addition to enterobiopsy with pathohistological analysis of small intestine mucosa as a basis for diagnosis of the disease, which was done in all 58 patients, in 45 of them, the level of anti-tissue transglutaminase (anti-TTG) antibodies was determined, and in 11 the presence of HLA DQ2 and HLA DQ8 genotype. Classification of pathohistological changes of the small intestinal mucosa was performed according to modified Marsh criteria on infiltrative (I), infiltrative-hyperplastic (II) destructive (III) and hypoplastic (IV) type [23]. According to the degree of mucosal damage, destructive enteropathy is additionally classified into partial (IIIa), subtotal (IIIb) and total (IIIc).

RESULTS

Except for four patients who were between the ages 1.75–2.50, out of 58 patients, all the others were over three years of age (Figure 1). The main clinical symptoms and signs suggestive of non-classical CD were anemia caused by iron deficiency (48.28%), short stature (34.48%), and intermittent abdominal pain (18.97%), anorexia with stagnation or weight loss (13.79%), and chronic constipation (6.9%) (Table 1). None of the patients had diarrhea. Most patients, 30 (51.72%), had one symptom or a sign of the disease, 15 had two and 13 had three. In addition, in 18 (30.03%) patients sideropenia without anemia was found, in 12 (20.69%) dental enamel hypoplasia, and in five mild isolated hypertransaminasemia (up to 1.5 times above the reference value).

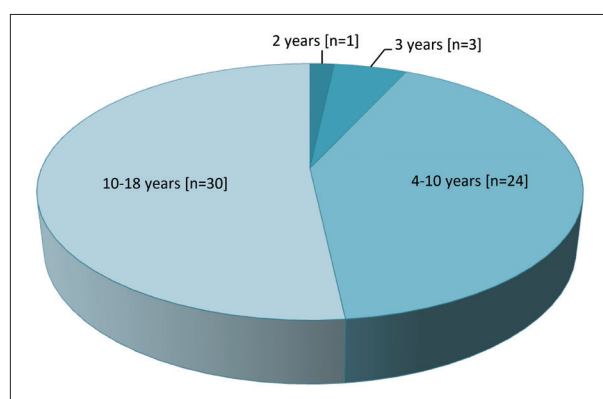


Figure 1. Distribution of our patients by age (n = 58)

Table 1. Symptoms and clinical signs that indicated nonclassical CD in our patients (n = 58)

Iron deficiency anemia	28
Short stature	20
Intermittent abdominal pain (> 2 months)	11
Anorexia and stagnation or weight loss	8
Chronic constipation (> 2 months)	4
Alopecia areata	2
Recurrent aphthous stomatitis	1
Dermatitis herpetiformis	1

The Hb values in the patient group with anemia ranged from 56–114 (93.11 ± 15.02) g/l. In 12 out of 28 patients, anemia was mild, moderate in 13, and severe in three patients. Serum iron levels in this group of patients were 1.2–10.5 (5.24 ± 2.33) $\mu\text{mol/l}$.

The degree of longitudinal growth retardation compared to the average for the appropriate age and sex in our 20 patients ranged from -10.5 to -19.22% (-13.65 \pm 2.07%). In 15 patients with short stature, the bone marrow was slowed 0.5–2.5 (1.57 ± 0.65) years. Other clinical and standard laboratory findings were within normal limits.

In all 45 patients who were tested for anti-TTG antibodies, level values were elevated. In 43 of them, the anti-TTG IgA class ranged from 28.6 to over 800 U/ml, while in two with a selective IgA deficiency, a high level of anti-TTG antibody IgG class (75.8 U/ml and over 1000 U/ml) was

recorded. In all 11 patients tested for “celiac HLA”, the presence of HLA DQ2 antigen was determined. Histological analysis of small intestinal mucus samples in 54 (93.10%) patients revealed a destructive enteropathy, in 15 partial (IIIa), in 23 subtotals (IIIb) and in 16 total (IIIc), while in only four it was infiltrative-hyperplastic (II). In addition to enteropathy, in three of our patients, lymphocytic gastritis has been identified.

With a gluten-free diet and oral iron administration in all patients with anemia, normal Hb and serum iron levels were registered within 2–4.5 months. Also, during 0.5–2 years of a gluten-free child, none of the patients with short stature had a height below the third percentile. A gluten-free diet, apart from the dental enamel hypoplasia, has resulted in the elimination of other symptoms and signs of the disease.

DISCUSSION

CD is etiopathogenetically multifactorial and clinically very heterogeneous autoimmune disease [1, 8]. With the development and application of modern highly sensitive and specific serological tests, in addition to clinically classic forms of the disease, today it is sovereign and more frequently diagnosed and its non-classical (atypical) and asymptomatic forms [1, 11]. Contribution to the improvement of diagnostics CD has also tested for the presence of HLA DQ2 and HLA DQ8 antigens as the main immunogenic markers of the disease [1, 11]. Although elevated levels of autoantibodies to tissue transglutaminase and endomycin and antibodies to deamidated gliadin, as well as the absence of HLA DQ2 and HLA DQ8 antigens do not have an absolute diagnostic value, their use is important in the selection of patients for enterobiopsy that remains the gold standard in the CD diagnostics [1, 9]. Bearing in mind the symptomatology that is also encountered in other pathological conditions, for the sake of reliable diagnostics, all of our patients were subjected to enterobiopsy with a pathohistological analysis of the small intestine mucosa. Excluding four patients, with verified infiltrative-hyperplastic enteropathy, in all other damage of the small intestinal mucosa was destructive type.

Unlike adults, CD in children is, in general, a reversible disease [11, 16, 24]. The only exception is dental enamel hypoplasia and in large part the gluten-induced cerebellar ataxia, which remains permanently, as well as short stature and reduced bone density if the disease is detected at the final stage of adolescence [11, 24, 25]. In addition, diagnostics and adequate CD treatment in childhood also prevent its complications that occur during adulthood, such as infertility in the generative period and fragility of the skeleton, peripheral neuropathy, dementia, and some malignancies in later years [1, 11]. That is why its detection and adequate treatment in the developmental period are of particular importance. A gluten-free diet as a key therapeutic measure, apart from the dental enamel hypoplasia, has resulted in the elimination of all indicators of the disease in our patients.

Nonclassical type of CD is usually discovered in children over the age of three [8, 17]. Except for four out of 58 patients, one in the second year and three in the third year, all others were older than three years.

Iron deficiency anemia and short stature is the most common extraintestinal manifestations of the pediatric CD, including its nonclassical subtype [11, 25, 26, 27]. In some cases, iron deficiency anemia or short stature may be the only signs of a CD [27, 28]. Other symptoms and signs of nonclassical CD, such as chronic constipation, recurrent abdominal pain, isolated hypertransaminasemia, osteopenia or osteoporosis, aphthous stomatitis, alopecia and others, are significantly less common or rare [11, 25, 26]. Although these symptoms and clinical signs do not have a specific character, in the context of their consideration, the nonclassical CD should be considered as a possible cause.

The basis of the iron deficiency in CD is the absorption disorder caused by the morphological and functional damage of the proximal part of the small intestine mucosa, i.e., in the segment where iron is absorbed [29]. As with other inflammatory diseases, additional involvement in iron malabsorption has a suppressive effect of hepcidin [29]. Negative iron balance in the CD is also significantly contributed by its insufficient intake caused by anorexia. In our group of patients, iron deficiency anemia was registered in 28 (48.28%) cases, of which in 12 (20.69%) as the only sign of CD. In addition, 18 (33.33%) patients were found to have sideropenia without anemia.

The pathogenesis of short stature in CD is a consequence of a negative nutritional balance, and possibly other factors, such as abnormalities in the growth hormone-insulin-like growth factor axis and/or thyroid function [11, 27]. It is usually associated with a delayed maturation, anemia, or some of its other symptoms and signs. Although it is a frequent sign of non-classical CD, impaired growth is particularly common in younger children with a classical form of the disease [11, 25, 26]. In our group of patients with nonclassical CD, short stature was established in 20 (34.48%) patients. In addition, in 15 of them it was identified delayed maturation and in 10 iron deficiency anemia.

Similar to the experiences of other authors, recurrent abdominal pain, vague loss of appetite with stagnation in body weight, isolated hypertransaminasemia and chronic constipation, either as the only manifestation or with associated anemia, as well as hypoplasia of the dental enamel, were relatively frequent abnormalities in the group of our patients with nonclassical subtype of CD [11, 16, 24].

Other findings, such as alopecia areata, recurrent aphthous stomatitis and dermatitis herpetiformis, were rare manifestations of a nonclassical CD and in a group of our patients [11, 16]. In addition to enteropathy, in three of our patients, lymphocytic gastritis was identified as not-so-rare and on a gluten-free diet reversible finding in the CD [30].

CONCLUSION

Nonclassical CD is characterized by a very heterogeneous and non-specific clinical presentation. According to our

findings, the main features of this subtype of CD are iron deficiency anemia and short stature, and then recurrent abdominal pain, vague loss of appetite with stagnation in body weight and chronic constipation. Although these symptoms and clinical signs occur in many other pathological conditions, as part of their etiological consideration must be borne in mind and nonclassical CD. Timely diagnostics and adequate therapy of nonclassical CD in developmental period has a special significance that is reflected not only in removing immediate problems, but also in the prevention of complications that occur in later stages of life.

REFERENCES

- Caio G, Volta U, Sapone A, Leffler DA, De Giorgio R, Catassi C, et al. Celiac disease: a comprehensive current review. *BMC Med.* 2019;17(1):142.
- Glissen Brown JR, Singh P. Coeliac disease. *Paediatr Int Child Health.* 2019;39(1):23–31.
- Márquez A, Kerick M, Zhernakova A, Gutierrez-Achury J, Chen WM, Onengut-Gumuscu S, et al. Meta-analysis of immunochip data of four autoimmune diseases reveals novel single-disease and cross-phenotype associations. *Genome Med.* 2018;10(1):97.
- Conti L, Lahner E, Galli G, Esposito G, Carabotti M, Annibale B. Risk factors associated with the occurrence of autoimmune diseases in adult coeliac patients. *Gastroenterol Res Pract.* 2018;2018:3049286.
- Choung RS, Larson SA, Khaleghi S, Rubio-Tapia A, Ovsyannikova IG, King KS, et al. Prevalence and morbidity of undiagnosed celiac disease from a community-based study. *Gastroenterology.* 2017;152(4):830–9.e5.
- Tye-Din JA, Galipeau HJ, Agardh D. Celiac disease: A review of current concepts in pathogenesis, prevention, and novel therapies. *Front Pediatr.* 2018;6:350.
- Escudero-Hernández C, Peña AS, Bernardo D. Immunogenetic pathogenesis of celiac disease and non-celiac gluten sensitivity. *Curr Gastroenterol Rep.* 2016;18(7):36.
- Branski D, Troncone R, Fasano A. Celiac disease (Gluten-sensitive enteropathy). In: Kliegman RM, Stanton BF, St Geme III JW, Schol NF, editors. *Nelson Textbook of Pediatrics.* 20th ed. Philadelphia: Elsevier; 2016. p.1835–8.
- Husby S, Koletzko S, Korponay-Szabó IR, Mearin ML, Phillips A, Shamir R, et al; ESPGHAN Working Group on Coeliac Disease Diagnosis; ESPGHAN Gastroenterology Committee; European Society for Pediatric Gastroenterology, Hepatology, and Nutrition. European Society for Pediatric Gastroenterology, Hepatology, and Nutrition guidelines for the diagnosis of coeliac disease. *J Pediatr Gastroenterol Nutr.* 2012;54(1):136–60.
- Ludvigsson JF, Leffler DA, Bai JC, Biagi F, Fasano A, Green PH, et al. The Oslo definitions for coeliac disease and related terms. *Gut.* 2013;62(1):43–52.
- Laurikka P, Nurminen S, Kivelä L, Kurppa K. Extraintestinal manifestations of celiac disease: Early detection for better long-term outcomes. *Nutrients.* 2018;10(8):1015.
- Jelsness-Jørgensen LP, Bernklev T, Lundin KEA. Fatigue as an extra-intestinal manifestation of celiac disease: A systematic review. *Nutrients.* 2018;10(11):1652.
- Busby E, Bold J, Fellows L, Rostami K. Mood disorders and gluten: It's not all in your mind! A systematic review with meta-analysis. *Nutrients.* 2018;10(11):1708.
- Pinto-Sánchez MI, Bercik P, Verdu EF, Bai JC. Extraintestinal manifestations of celiac disease. *Dig Dis.* 2015;33(2):147–54.
- Gujral N, Freeman HJ, Thomson AB. Celiac disease: prevalence, diagnosis, pathogenesis and treatment. *World J Gastroenterol.* 2012;18(42):6036–59.
- Jericho H, Sansotta N, Guandalini S. Extraintestinal manifestations of celiac disease: Effectiveness of the gluten-free diet. *J Pediatr Gastroenterol Nutr.* 2017;65(1):75–9.
- Radlović N. Celiac disease. *Srp Arh Celok Lek.* 2013;141(1–2):122–6.
- Walker-Smith JA, Guandalini S, Schmitz J, Shmerling DH, Visakorpi JK. Revised criteria for diagnosis of coeliac disease. Report to working group of European Society of Paediatric Gastroenterology and Nutrition. *Arch Dis Child.* 1990;65(8):909–11.
- Needelman RD. Growth and development. In: Behrman RE, Kliegman RM, Jenson HB, editors. *Nelson Textbook of Pediatrics,* 17th ed. Philadelphia:WB Saunders Comp; 2004. p. 23–66.
- Greulich WW, Pyle SI. *Radiographic Atlas of Skeletal Development of Hand Wrist.* 2. Stanford University Press; Stanford CA: 1971.
- Lo SF. Laboratory testing in infants and children In: Behrman RE, Kliegman RM, Stanton, St Geme III JW, Schor NF. *Nelson Textbook of Pediatrics,* 20th ed. Philadelphia:WB Saunders Comp; 2016. p. 3460–73.
- WHO. Haemoglobin concentrations for the diagnosis of anaemia and assessment of severity. *Vitamin and Mineral Nutrition Information System.* Geneva, World Health Organization, 2011 (WHO/NMH/NHD/MNM/11.1)
- Oberhuber G, Granditsch G, Vogelsang H. The histopathology of coeliac disease: time for a standardized report scheme for pathologists. *Eur J Gastroenterol Hepatol.* 1999;11(10):1185–94.
- Nardocchia S, Auricchio R, Discepolo V, Troncone R. Extra-intestinal manifestations of coeliac disease in children: Clinical features and mechanisms. *Front Pediatr.* 2019;7:56.
- Jericho H, Guandalini S. Extra-intestinal manifestation of celiac disease in children. *Nutrients.* 2018;10(6):755.
- Semwal P, Gupta RK, Sharma R, Garg K. Comparison of endoscopic and histological findings between typical and atypical celiac disease in children. *Pediatr Gastroenterol Hepatol Nutr.* 2018;21(2):86–92.
- Cornean RE, Gheban D, Simionescu B, Margescu M. Celiac disease among adolescents. Poor growth and delayed puberty. *Internat J Celiac Dis.* 2018;6(2):52–7.
- Singh P, Makharia GK. Non-classical celiac disease: Often missed. *Internat J Celiac Dis.* 2014;2(3):76–85.
- Freeman HJ. Iron deficiency anemia in celiac disease. *World J Gastroenterol.* 2015;21(31):9233–8.
- Gabrieli D, Ciccone F, Capannolo A, Viscido A, Valerii G, Serva D, et al. Subtypes of chronic gastritis in patients with celiac disease before and after gluten-free diet. *United European Gastroenterol J.* 2017;5(6):805–10.

ACKNOWLEDGEMENT

We would like to express our deep gratitude to the pathologists from the Institute of Pathology of the Medical Faculty of the University of Belgrade, Professor Ana Laban, and Professor Zorica Stojić, for many years of cooperation in diagnosing this and many other diseases we had in our practice.

Conflict of interest: None declared.

Клинички симптоми неklasичне целијачне болести код деце и адолесцената

Недељко Радловић¹, Зоран Лековић^{2,3}, Владимир Радловић^{2,3}, Јелена Мандић⁴, Марија Младеновић⁵, Јелена Радловић⁶, Биљана Вулетић^{7,8}, Сениша Дучић^{2,3}, Бојан Буква^{2,3}, Ивана Дашић²

¹Академија медицинских наука Српског лекарског друштва, Београд, Србија;

²Универзитетска дечја клиника, Београд, Србија;

³Универзитет у Београду, Медицински факултет, Београд, Србија;

⁴Универзитет у Београду, Стоматолошки факултет, Клиника за дечју и превентивну стоматологију, Београд, Србија;

⁵Универзитет „Сингидунум“, Факултет здравствених, правних и пословних студија, Ваљево, Србија;

⁶Завод за здравствену заштиту радника „Железнице Србије“, Београд, Србија;

⁷Клинички центар Крагујевац, Клиника за педијатрију, Крагујевац, Србија;

⁸Универзитет у Крагујевцу, Факултет медицинских наука, Крагујевац, Србија

САЖЕТАК

Увод/Циљ Некласичну целијачну болест (ЦБ) карактерише врло хетерогено и неспецифично клиничко испољавање.

Циљ ове студије био је да се утврде основни симптоми и клинички знаци овог подтипа ЦБ код деце и адолесцената.

Методе Студија је базирана на узорку од 58 деце и адолесцената, 38 женског и 20 мушког пола, узраста од 1,75 до 17,75 (10,01 ± 4,62) година, са неklasичном ЦБ дијагностикованом у складу са критеријумима Европског удружења за дечју гастроентерологију из 1990. и 2012. године.

Резултати Осим четворо болесника који су били у доби од 1,75 до 2,50 година, сви остали су били старији од три године. Главни клинички симптоми и знаци који су указивали на неklasичну ЦБ били су анемија узрокована недостатком гвожђа (48,28%), низак раст (34,48%), повремени болови у трбуху (18,97%), анорексија са застојем или губитком телес-

не тежине (13,79%) и хронична опстипација (6,90%). Један симптом или знак болести имало је 30 болесника, 15 два и 13 три. Поред тога, 18 болесника су имали сидеропенију без анемије, 12 хипоплазију зубне глеђи и пет благу изоловану хипертрансaminaсемију. Дијета без глутена, осим хипоплазије зубне глеђи, резултирала је повлачењем свих показатеља болести.

Закључак Главни симптоми и клинички знаци неklasичне ЦБ код деце и адолесцената су анемија узрокована недостатком гвожђа, низак раст и повремени болови у трбуху, а ређе анорексија са стагнацијом или губитком тежине и хронична опстипација. Изузимајући хипоплазију зубне глеђи, дијета без глутена доводи до потпуног опоравка болесника.

Кључне речи: неklasична целијачна болест; деца и адолесценти; симптоми и знаци