



CASE REPORT / ПРИКАЗ БОЛЕСНИКА

A multisystem inflammatory syndrome in children associated with COVID-19 in an 11-year-old girl

Milena Bjelica^{1,2}, Gordana Vilotijević-Dautović^{1,2}, Andrea Đuretić¹, Slobodan Spasojević^{1,2}

¹Institute for Child and Youth Health Care of Vojvodina, Novi Sad, Serbia;

²University of Novi Sad, Faculty of Medicine, Novi Sad, Serbia

SUMMARY

Introduction Multisystem inflammatory syndrome in children (MIS-C) is a post-viral, life-threatening, inflammatory state with multisystem involvement that typically manifests 3–4 weeks after SARS-CoV-2 infection. In this article, we present the first case of MIS-C at the Institute for Child and Youth Health Care of Vojvodina at the beginning of the COVID-19 pandemic.

Case outline A previously healthy 11-year-old girl got sick two days before admission to the hospital with a fever, headache, vomiting, abdominal pain, and fatigue. She was tested positive for COVID-19 by a nasopharyngeal PCR swab with positive IgM and IgG antibodies. In the further course, the illness presented with prolonged fever, laboratory evidence of inflammation, multiorgan involvement such as respiratory, gastrointestinal, cardiovascular, and dermatologic. Based on CDC and WHO criteria, the diagnosis of MIS-C was made and IVIG and methylprednisolone were introduced with favorable clinical course.

Conclusion Every prolonged and unusual febrile state, especially if it is accompanied by gastrointestinal symptoms, in a school-age child, should be investigated in the direction of recent COVID-19 infection or exposure. In a case of a positive COVID-19 history or history of exposure, the MIS-C diagnosis should be considered.

Keywords: SARS-CoV-2; child; inflammation; immunoglobulins; glucocorticoids

INTRODUCTION

Initially, the SARS-CoV-2 infection was not considered to be a severe infection in children. However, the first cases of multisystem inflammatory syndrome in children (MIS-C) showed the potential of this virus to produce a life-threatening state with multisystem involvement [1, 2]. Still, the vast majority of children with COVID-19 present with mild symptoms and have excellent outcomes. MIS-C remains a rare complication of SARS-CoV-2 infection in the pediatric population [2, 3]. The mortality rate of MIS-C is 1.7–1.8% [4, 5].

MIS-C has been defined by the Center for Disease Control and Prevention (CDC) and the World Health Organization (WHO). Both definitions are similar and include the same main criteria: age under 21 years (CDC) or 19 years (WHO), fever for more than one day (CDC) or three days (WHO), clinical signs of multisystem involvement, laboratory evidence of inflammation, no alternative diagnosis and evidence of SARS-CoV-2 infection or exposure [6, 7]. MIS-C is a post-viral inflammatory state that typically manifests 3–4 weeks after SARS-CoV-2 infection and may rapidly progress to multiorgan failure [1, 4, 8]. Rarely, MIS-C occurs during the acute phase of SARS-CoV-2 infection [2]. Clinical presentation of MIS-C may have some overlapping features with Kawasaki disease (KD) and toxic shock syndrome but is presently understood to be a

separate phenomenon [1]. Unlike traditional KD, affected patients with MIS-C often require intensive care and additional targeted therapy against the inflammatory response [8].

In this article, we present the first case of MIS-C in the Institute for Child and Youth Health Care of Vojvodina at the beginning of the COVID-19 pandemic.

CASE REPORT

A previously healthy 11-year-old girl, apart from congenital hypothyroidism (well controlled with oral levothyroxine replacement therapy), with the 75% of body weight and height, got sick two days before admission to the hospital with a fever, headache, vomiting, abdominal pain, and fatigue. Upon admission, the patient tested positive for COVID-19 by a nasopharyngeal PCR swab. IgM and IgG antibodies to SARS-CoV-2 were positive. No other family members were tested and all remained asymptomatic. On admission laboratory tests revealed an elevated C-reactive protein (CRP) of 11.6 mg/dL with a leukocyte count of $5.8 \times 10^9/L$, neutrophilia (84.7%), and lymphopenia (3%). An abdominal ultrasound was performed and was inconclusive for appendicitis; enlarged mesenteric lymph nodes were found. Oral intake was stopped, parenteral hydration started and the patient was observed for the acute surgical abdominal disease. On the second day of hospitalization,

Received • Примљено:

May 10, 2021

Accepted • Прихваћено:

September 9, 2021

Online first: September 13, 2021

Correspondence to:

Milena BJELICA
Institute of Child and Youth
Health Care of Vojvodina
Hajduk Veljkova 10
21000 Novi Sad
Serbia

milena.bjelica@mf.uns.ac.rs

the patient remained febrile with the appearance of tachypnea, dry cough, and episodes of oxygen desaturations. The patient developed red and cracked lips, macular rash on limbs with petechiae on the feet, and swelling of the ankles. The acute phase reactants continued to increase (CRP 21.5 mg/dL, procalcitonin 1.6 ng/mL, ERS 62 mm/hr, fibrinogen 4,57 g/l, IL6 1077 pg/ml, ferritin 385 ug/L. D-dimer values were elevated (over 2500 ng/mL) with prolonged PT and PTT. Troponin I (95.5 ng/mL) was also elevated. There was hypoalbuminemia (34 g/L), slightly elevated uric acid values (362 umol/L), elevated aspartate aminotransferase (AST) values (0.480 ukat/L). T3 and TSH were decreased, T4 was in a normal range. Other parameters of renal, hepatic, and pancreatic function were normal, as well as LDH and lipid profile. Serum immunoglobulin levels and serum components of complement C3 and C4 were in a normal range. Antinuclear antibodies were positive. Anti-neutrophil cytoplasmic antibodies, anticardiolipin antibodies, beta-2 glycoprotein antibodies, anti-double stranded DNA antibodies, and anti-cyclic citrullinated peptides were negative. Blood, urine, and stool cultures were negative. A chest radiograph was performed to verify bilateral interstitial pneumonia (Figure 1). Oxygen therapy and antibiotic therapy (ceftriaxone, metronidazole, azithromycin) were introduced. Since the patient had pneumonia and confirmed SARS-CoV-2 infection, according to the RECOVERY collaborative group recommendations, parenteral corticosteroid therapy (dexamethasone 0.15 mg/kg, 6 mg) was started. Vitamin C and vitamin D were also introduced. Initially, nadroparin was given, followed by acetylsalicylic acid.

The patient was treated by a multidisciplinary team including a pediatric pulmonologist, immunologist, hematologist, intensive care pediatrician, and surgeon.

On the fourth day of hospitalization, fever persisted, as well as abdominal pain with the further increase of the acute phase reactants (CRP 22.8 mg/dL, procalcitonin 2.5 ng/ml). Additional blood cultures were negative. Echocardiography verified pericardial effusion of 6mm with no changes in coronary arteries and normal ejection fraction. The lung ultrasound revealed bilateral pleural effusions up to 19 mm. The abdominal ultrasound showed the non-compressible appendix surrounded by reactively altered adipose tissue. The pediatric surgeon recommended appendectomy which was done and catarrhal appendicitis was found.

Antibiotic therapy was changed, meropenem and linezolid were introduced. Since the patient was febrile with laboratory evidence of inflammation, multiorgan involvement such as respiratory, gastrointestinal, cardiovascular, and dermatologic and proven SARS-CoV-2 infection, the multidisciplinary team considered MIS-C. The intravenous immunoglobulins (IVIg) at a dose of 2 g/kg (1 g/kg for two days) were introduced on the fourth day of hospitalization, and methylprednisolone at a dose of 2 mg/kg/day was introduced on the fifth hospital day. The day after the introduction of IVIg, IL-6 levels halved (561 pg/ml) with a constant decrease in the further course. The level of CRP started decreasing two days after the introduction of IVIg and methylprednisolone. Levels of procalcitonin continued

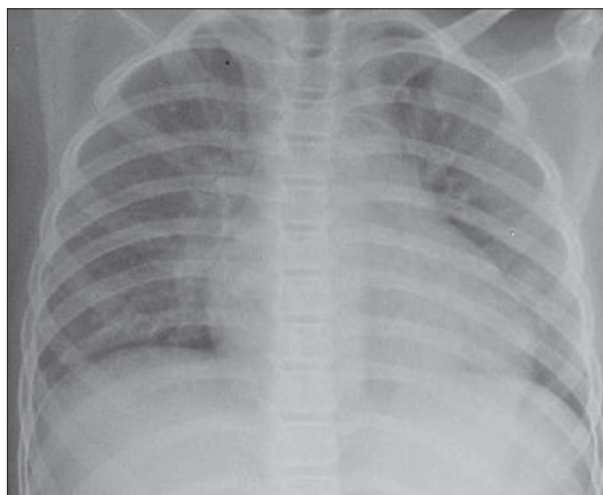


Figure 1. The chest X-ray of the 11-year-old girl with multisystem inflammatory syndrome associated with COVID-19 bilateral ground glass opacities

to rise until the fifth hospital day (maximum 25.9 ng/ml) and then decreased slowly. Ferritin levels increased to the maximum level of 468 µg/l on the fifth hospital day and then started to decrease slowly. The further clinical course was complicated with the appearance of acute renal injury (urea 12.9 mmol/L, creatinine 129.1 µmol/L, uric acid 417 µmol/L), hypotension, and signs of shock. Acute renal failure was treated conservatively. Due to hypotension, a vasopressor (norepinephrine) was introduced. There was a good clinical response to the applied therapy. The patient became afebrile from the fifth day of hospitalization with a gradual normalization of the acute phase reactants as well as renal function parameter levels. There was also a gradual cardiovascular and respiratory recovery with normalization of the chest radiograph and lung ultrasound. From the 12th day of hospitalization, no oxygen therapy was needed. The further clinical course was complicated with acute pancreatitis (amylase 4.36 ukat/L, lipase 4.22 ukat/L), which was treated conservatively. After 23 days the patient was discharged from the hospital in a good general condition. During a regular check-up, she complained of occasional chest pain and increased hair loss that resolved after a couple of months. Control chest X-ray, laboratory, and echocardiography findings were normal.

We confirm that we have read the journal's position on issues involving ethical publication and affirm that this work is consistent with those guidelines.

All procedures performed in studies involving human participants were in accordance with the ethical standards of the institutional and/or national research committee and with the 1964 Helsinki declaration and its later amendments or comparable ethical standards. Written consent to publish all shown material was obtained from the patient.

DISCUSSION

MIS-C associated with SARS-CoV-2 is thought to occur due to a dysregulated innate immune response and a

subsequent cytokine storm and endothelial damage that affects numerous organ systems [8, 9]. Still, much remains unknown regarding epidemiology, pathogenesis, clinical spectrum, and long-term outcomes of MIS-C [9].

We present the first case of MIS-C in our Institute in the first months of the COVID-19 pandemic.

It is known that children can develop MIS-C 3–4 weeks after a symptomatic or asymptomatic COVID-19 infection, often causing the patients with MIS-C to have positive antibodies to SARS-CoV-2 and negative PCR. This suggests that MIS-C is not mediated by direct viral invasion, but coincides with the development of the acquired immune response to SARS-CoV-2. In a minority of cases, MIS-C occurs during the acute phase of SARS-CoV-2 infection. This underlines the necessity of meticulous follow-up of children with COVID-19 infection even when they don't have serious symptoms [2, 4, 9]. Our patient at the time of MIS-C presentation had both positive PCR and IgM and IgG antibodies. As the SARS-CoV-2 infection in children is usually asymptomatic with no multiorgan involvement, and since the PCR test may still be positive several days after infection, a multiorgan presentation in our patient is considered to be MIS-C.

Until today, risk factors for developing MIS-C are not completely defined. The literature data show that the mean age at presentation is around nine years with no specific difference between genders [4, 5, 10]. Our patient is a 11-year-old girl, slightly older than the published mean age. Some studies in the USA showed that there was a higher rate of MIS-C in the African American/Afro-Caribbean population, suggesting genetic susceptibility. Obesity in children is considered to be a risk factor due to an accumulation of inflammatory cells in adipose tissue, impaired respiratory function, and more SARS-CoV-2 binding receptors in adipose cells [4]. Our patient had body weight on the 75%, slightly above the average, but still was not obese.

Diagnosing MIS-C can be challenging, especially when it develops after the episode of asymptomatic or unrecognized COVID-19 infection. MIS-C can start with nonspecific symptoms and over time can develop all necessary criteria defined by CDC and WHO [4, 6, 7]. The obligatory criterion is prolonged fever, as it was in the case of our patient. Other usual symptoms are gastrointestinal, which occur in around 70% of patients with MIS-C [4]. Vomiting and abdominal pain can be so intense to mimic acute appendicitis [4, 5, 8, 10]. The same clinical picture was present in our patient, which was firstly observed in the light of acute abdominal disease and undergone an appendectomy. In the three weeks clinical course she also developed pancreatitis, as previously was described in the literature as one of the spectra of gastrointestinal pathology in MIS-C [11]. Other clinical signs and symptoms of MIS-C are: respiratory, cardiovascular, renal, hematological, neurological, and dermatological [6, 7]. Our patient had bilateral pleuropneumonia, hypotension, shock, pericarditis, acute kidney injury, coagulopathy, and skin rash. All these clinical signs appeared in the latter course, after the initial gastrointestinal presentation.

Elevated markers of inflammation are among the criteria of the case definition of MIS-C. They include elevated CRP, ESR, fibrinogen, procalcitonin, D-dimer, ferritin, LDH, IL-6 levels, neutrophilia, lymphocytopenia, and hypoalbuminemia [6, 7]. All these criteria were fulfilled in the case of our patient, except elevated LDH.

One of the criteria for making the diagnosis of MIS-C is the exclusion of other obvious microbial causes or inflammation. Multiple bloods, urine, and stool cultures in our patient were negative. Also, immunological analyses were done and all results were normal, except positive antinuclear antibodies.

One of the problems with making the diagnosis of MIS-C is that it resembles KD. Still, there are few important differences. Firstly, KD occurs in young children under five years of age, whereas the mean age in MIS-C is nine years. Secondly, there is an increased incidence of MIS-C in patients of African, Afro-Caribbean, and Hispanic descent, but a lower incidence in those of East Asian descent, in contrast to KD [4]. Thirdly, the inflammatory storm observed in MIS-C is much more intense with a greater elevation of inflammatory markers. At presentation, patients with MIS-C tend to have higher CRP levels, lower platelet counts, and lower absolute lymphocyte counts than patients with KD. Fourthly, the clinical presentation of KD and MIS-C is slightly different. Distinguishing clinical characteristics found in MIS-C are vomiting, diarrhea, abdominal pain, shock, and cardiac dysfunction, while they could be present, but are not usual in KD. MIS-C and KD may share overlapping clinical features, including fever, conjunctival injection, oropharyngeal findings (red and/or cracked lips, strawberry tongue), rash, swollen and/or erythematous hands, and feet, and cervical lymphadenopathy [3, 4]. According to the published data conjunctivitis and rash are present in around 50% of children with MIS-C [4]. Epidemiologic studies of MIS-C suggest that younger children are more likely to present with KD-like features while older children are more likely to develop myocarditis and shock [3, 4]. Our patient, although an older child, had the clinical picture that mimics KD with prolonged fever, oropharyngeal changes, rash, and swelling of the ankles. Still, she did not have the enlargement of cervical lymph nodes and bilateral bulbar conjunctival injections and no other criteria for KD. On the other hand, predominant symptoms were gastrointestinal with the further involvement of other organ systems; laboratory findings were consistent with MIS-C and SARS-CoV-2 infection was confirmed. These are reasons why our patient was diagnosed and treated as MIS-C.

The overlapping characteristics between these syndromes might suggest that they may have similar pathophysiology and as a consequence similar therapeutical approach. Most children with MIS-C recover with standard KD therapies, IVIG, and glucocorticoids and only a small number of patients require immunomodulating agents, such as IL-1 or IL-6 antagonists. The majority of the children with MIS-C need some degree of intensive care, most often respiratory support and inotropes [3, 4, 9]. There are no widely accepted guidelines concerning the

therapy of MIS-C, but several organizations have published their guidelines [3, 12–17]. The combination of IVIG and methylprednisolone has been proven to be associated with a more favorable fever course in patients with MIS-C than IVIG alone [18]. Our patient had a good clinical response to IVIG and glucocorticoid therapy (initially dexamethasone, then methylprednisolone). Vitamin C, vitamin D, and initially nadroparin followed with acetylsalicylic acid, were also introduced. During the first 12 days of hospitalization oxygen therapy was required as well as the inotropes in the further course.

It is currently unknown whether MIS-C has potential long-term sequelae [4, 9]. It is known that the inflammatory disorders triggered by SARS-CoV-2 can result in coronary aneurysms, so cardiac assessment and follow-up are essential in all cases [9]. It is unknown if the incidence of coronary artery aneurysms (CAA) is different in MIS-C compared to KD. However, MIS-C patients without KD features can develop CAA [3]. A follow-up of our patient revealed the occasional chest pain and increased hair

loss in the weeks following discharge from the hospital. Echocardiography and 24-hour ECG monitoring were without pathological changes and all laboratory analyses were within referral ranges, including control antinuclear antibodies which were negative. These symptoms disappeared after a few months.

This case report highlights the necessity of close monitoring of children during and after COVID-19. Every prolonged and unusual febrile state, especially if it is accompanied by gastrointestinal symptoms, in a school-age child should be investigated in the direction of recent COVID-19 infection or exposure. In a case of a positive COVID-19 history or history of exposure, the MIS-C diagnosis should be considered. Otherwise, the child should be observed for any other cause of the febrile state, including other infections or KD. Overlaps in the clinical picture of MIS-C, KD, and acute appendicitis should be kept in mind in order to make the right diagnosis and introduce the appropriate treatment.

Conflict of interest: None declared.

REFERENCES

- Kest H, Kaushik A, DeBruin W, Colletti M, Goldberg D. Multisystem Inflammatory Syndrome in Children (MIS-C) Associated with 2019 Novel Coronavirus (SARS-CoV-2) Infection. *Case Rep Pediatr*. 2020;2020:8875987.
- Esposito S, Principi N. Multisystem Inflammatory Syndrome in Children Related to SARS-CoV-2. *Paediatr Drugs*. 2021;23(2):119–29.
- Ahmed M, Advani S, Moreira A, Zoretic S, Martinez J, Chorath K, et al. Multisystem inflammatory syndrome in children: A systematic review. *EClinicalMedicine*. 2020;26:100527.
- Godfred-Cato S, Bryant B, Leung J, Oster ME, Conklin L, Abrams J, et al. COVID-19-Associated Multisystem Inflammatory Syndrome in Children – United States, March – July 2020. *MMWR Morb Mortal Wkly Rep*. 2020;69(32):1074–80.
- Henderson LA, Canna SW, Friedman KG, Gorelik M, Lapidus SK, Bassiri H, et al. American College of Rheumatology Clinical Guidance for Pediatric Patients with Multisystem Inflammatory Syndrome in Children (MIS-C) Associated with SARS-CoV-2 and Hyperinflammation in COVID-19. *Arthritis Rheumatol*. 2020;72(11):1791–805.
- Center for Disease Control and Prevention, US Department of Health & Human Services. Multisystem inflammatory syndrome in children (MIS-C) associated with coronavirus disease 2019 (COVID-19), 2020. Available: <https://emergency.cdc.gov/han/2020/han00432.asp>
- Freedman S, Godfred-Cato S, Gorman R, Lodha R, Mofenson L, Murthy S, et al. Multisystem inflammatory syndrome in children and adolescents temporally related to COVID-19, 2020. Available: <https://www.who.int/news-room/commentaries/detail/multisystem-inflammatory-syndrome-in-children-and-adolescents-with-covid-19>.
- Mahajan N, Chang HT, Leeman R, Manalo R, Glaberson WR. Case of multisystem inflammatory syndrome in children presenting as fever and abdominal pain. *BMJ Case Rep*. 2020;13(9):e237306.
- Jiang L, Tan K, Levin M, Irfan O, Morris SK, Wilson K, et al. COVID-19 and Multisystem Inflammatory Syndrome in Children and Adolescents. *Lancet Infect Dis*. 2020;20(11):e276–e288.
- Whitaker E, Bamford A, Kenny J, Kaforou M, Jones CE, Shah P, et al. Clinical characteristics of 58 children with a pediatric inflammatory multisystem syndrome temporally associated with SARS-CoV-2. *JAMA*. 2020;324(3):e2010369.
- Stevens JP, Brownell JN, Freeman AJ, Bashaw H. COVID-19-Associated Multisystem Inflammatory Syndrome in Children Presenting as Acute Pancreatitis. *J Pediatr Gastroenterol Nutr*. 2020;71(5):669–71.
- Children's Hospital of The King's Daughters. CHKD Treatment Guideline for COVID-19 in Children. Available: <https://www.chk.org/uploadedFiles/Documents/COVID-19/CHKD%20COVID%2019%20treatment%20guideline.pdf>
- Children's Hospital of Philadelphia. Emergency Department, ICU and Inpatient Clinical Pathway for Evaluation of Possible Multisystem Inflammatory Syndrome in Children (MIS-C). Available: <https://www.chop.edu/clinical-pathway/multisystem-inflammatory-syndrome-mis-c-clinical-pathway>
- Dove ML, Jaggi P, Kelleman M, Abuali M, Ang JY, Ballan W, et al. Multisystem Inflammatory Syndrome in Children: Survey of Protocols for Early Hospital Evaluation and Management. *J Pediatr*. 2021;229:33–40.
- Hennon TR, Penque MD, Abdul-Aziz R, Alibrahim OS, McGreevy MB, Prout AJ, et al. COVID-19 associated Multisystem Inflammatory Syndrome in Children (MIS-C) guidelines; a Western New York approach. *Prog Pediatr Cardiol*. 2020;101232.
- Harwood R, Allin B, Jones CE, Whittaker E, Ramnarayan P, Ramanan AV, et al. A national consensus management pathway for paediatric inflammatory multisystem syndrome temporally associated with COVID-19 (PIMS-TS): results of a national Delphi process. *Lancet Child Adolesc Health*. 2021;5(2):133–41.
- Cattalini M, Taddio A, Bracaglia C, Cimaz R, Paolera SD, Filocamo G, et al. Childhood multisystem inflammatory syndrome associated with COVID-19 (MIS-C): a diagnostic and treatment guidance from the Rheumatology Study Group of the Italian Society of Pediatrics. *Ital J Pediatr*. 2021;47(1):24.
- Ouldali N, Toubiana J, Antona D, Javouhey E, Madhi F, Lorrot M, et al. Association of Intravenous Immunoglobulins Plus Methylprednisolone vs Immunoglobulins Alone With Course of Fever in Multisystem Inflammatory Syndrome in Children. *JAMA*. 2021;325(9):855–64.

Мултисистемски инфламаторни синдром код деце повезан са болешћу COVID-19 код девојчице узраста 11 година

Милена Бјелица^{1,2}, Гордана Вилотијевић-Даутовић^{1,2}, Андреа Ђуретић¹, Слободан Спасојевић^{1,2}

¹Институт за здравствену заштиту деце и омладине Војводине, Нови Сад, Србија;

²Универзитет у Новом Саду, Медицински факултет, Нови Сад, Србија

САЖЕТАК

Увод Мултисистемски инфламаторни синдром код деце животно је угрожавајуће инфламаторно стање са мултисистемском презентацијом које се типично јавља 3-4 недеље после инфекције SARS-CoV-2. У овом раду приказујемо први случај мултисистемског инфламаторног синдрома код деце на Институту за здравствену заштиту деце и омладине Војводине на почетку пандемије болести COVID-19.

Приказ болесника Претходно здрава девојчица узраста 11 година разболела се појавом фебрилности, малаксалости, главобоље, повраћања и болова у трбуху. PCR тест на SARS-CoV-2 из назофарингеалног бриса је био позитиван, као и ИгМ и ИгГ антитела на SARS-CoV-2. У даљем току фебрилност се одржавала уз лабораторијске показатеље инфламације и мултиорганску презентацију укључујући респираторни, гастроинтестинални, кардиоваскуларни систем и кожне про-

мене. На основу критеријума Центра за контролу и превенцију болести и Светске здравствене организације постављена је дијагноза мултисистемског инфламаторног синдрома код деце и започета је терапија интравенским имуноглобулинама и метилпреднизолоном са добрим одговором на примењену терапију и повољним клиничким током.

Закључак Свако пролонгирано или неуобичајено фебрилно стање код школског детета, нарочито ако је праћено гастроинтестиналним симптомима, треба да буде испитано у правцу претходне инфекције COVID-19 или изложености овом вирусу. Уколико постоје анамнестички подаци о инфекцији COVID-19 или њеној изложености, потребно је размотрити мултисистемски инфламаторни синдром код деце.

Кључне речи: SARS-CoV-2; дете; инфламација; имуноглобулини; кортикостероиди