



СРПСКИ АРХИВ
ЗА ЦЕЛОКУПНО ЛЕКАРСТВО
SERBIAN ARCHIVES
OF MEDICINE

Address: 1 Kraljice Natalije Street, Belgrade 11000, Serbia

+381 11 4092 776, Fax: +381 11 3348 653

E-mail: office@srpskiarhiv.rs, Web address: www.srpskiarhiv.rs

Paper Accepted*

ISSN Online 2406-0895

Case report / Приказ болесника

Ivana Bajkin^{1,2,*}, Slađana Pejaković^{1,2}, Mia Manojlović^{1,2}, Ivana Vorgučin^{1,3}, Dragana Tomić Naglić^{1,2}

Forgotten Cause of Severe Hyponatremia

Занемарени узрок хипонатремије тешког степена

¹University of Novi Sad, Faculty of Medicine, Novi Sad, Serbia;

²Clinical Center of Vojvodina, Clinic for Endocrinology, Diabetes and Metabolic Disorders, Novi Sad, Serbia;

³Institute for Child and Youth Health Care of Vojvodina, Pediatric Clinic, Novi Sad, Serbia

Received: May 7, 2021

Revised: July 19, 2021

Accepted: July 21, 2021

Online First: July 26, 2021

DOI: <https://doi.org/10.2298/SARH210507067B>

* **Accepted papers** are articles in press that have gone through due peer review process and have been accepted for publication by the Editorial Board of the *Serbian Archives of Medicine*. They have not yet been copy-edited and/or formatted in the publication house style, and the text may be changed before the final publication.

Although accepted papers do not yet have all the accompanying bibliographic details available, they can already be cited using the year of online publication and the DOI, as follows: the author's last name and initial of the first name, article title, journal title, online first publication month and year, and the DOI; e.g.: Petrović P, Jovanović J. The title of the article. *Srp Arh Celok Lek*. Online First, February 2017.

When the final article is assigned to volumes/issues of the journal, the Article in Press version will be removed and the final version will appear in the associated published volumes/issues of the journal.

The date the article was made available online first will be carried over.

***Correspondence to:**

Ivana BAJKIN

Clinical Center of Vojvodina, Clinic for Endocrinology, Diabetes and Metabolic Disorders,

Hajduk Veljkova 1-9, 21000 Novi Sad, Serbia,

E-mail: ivana.bajkin@mf.uns.ac.rs

Forgotten Cause of Severe Hyponatremia

Занемарени узрок хипонатремије тешког степена

SUMMARY

Introduction Sheehan syndrome (ShS) is (pan)hypopituitarism because of postpartum pituitary infarction due to massive obstetrical hemorrhage. Enlargement of the pituitary gland, smaller sellar region, disseminated intravascular coagulation (DIC) or autoimmunity are predisposing factors. The absence of lactation after labor and inability to resume the menstrual cycle later are presenting symptoms. Some of patients with Sheehan's syndrome have a sudden onset of severe hypopituitarism immediately after labor, most often in the form of severe hyponatremia. Central adrenal insufficiency is the most usual cause of hyponatremia, although in some cases the syndrome of inappropriate antidiuretic hormone secretion has been also described.

Case outline The female patient, 39-year-old, was admitted to the Intensive Care Unit due to severe hyponatremia with neurological symptoms (Na 103 mmol/L, Cl 72 mmol/L, K 3.7 mmol/L), and absence of lactation. Previously, on the sixth postpartum day, she was admitted to the Obstetrics and Gynecology Clinic due to severe headache, nausea, vomiting, and blurred vision. The symptoms persist from the labor, which was complicated with severe hemorrhage (1000 ml) due to obstetric complications. Treatment began with the 3% hypertonic saline solution with restriction of fluid intake. In regard to panhypopituitarism, replacement therapy with hydrocortisone and levothyroxine was initiated. Diabetes insipidus was excluded. Growth hormone replacement therapy and combination of progesterone and progestogens was started during follow-up.

Conclusion Early diagnosis of Sheehan's syndrome is essential. Pituitary insufficiency in these patients has a great diversity in presentation, that can sometimes result in coma and death.

Keywords: postpartum hemorrhage; Sheehan syndrome; panhypopituitarism

САЖЕТАК

Увод Шиханов синдром (*Sheehan syndrome*) настаје услед исхемијске некрозе хипофизе због постпарталног крварења, а карактерише га различит степен хипопитуитаризма. Повећан волумен хипофизе, мања селарна регија, дисеминована интраваскуларна коагулација или аутоимуност су предиспонирајући фактори. Изостанак лактације постпартално и касније немогућност успостављања менструационог циклуса су најчешћи презентујући симптоми. Мали број пацијенткиња са Шихановим синдромом има наглан настанак тешког хипопитуитаризма непосредно постпартално, најчешће у виду хипонатремије тешког степена која се може детектовати већ у акутној фази након порођаја. Централна адренална инсуфицијенција је највероватнији узрок хипонатремије, мада је у појединим случајевима описан и синдром неадекватне секреције антидиурезног хормона.

Приказ болесника Пацијенткиња, стара 39 година, примљена је на Одељење ургентне интерне медицине због тешке хипонатремије праћене неуролошким симптоматологијом (Na 103 mmol/L, Cl 72 mmol/L, K 3,7 mmol/L), уз податак о изостанку лактације. Претходно је шестог постпарталног дана рехоспитализована на Клинику за гинекологију и акушерство, због тешке главобоље, мучнине, повраћања, замућења вида. Тегобе перзистирају од момента терминског вагиналног порођаја, током ког је болесница изгубила око 1000 ml крви због акушерских компликација. Започето је лечење применом хипертоног раствора натријума уз накнадну рестрикцију уноса течности. У оквиру дијагностикованог панхипопитуитаризма започета је супституциона терапија хидрокортизоном и потом левотироксином. Искључено је постојање инсипидног дијабетеса. Током даљег праћења, уведена је супституциона терапија хормоном раста и комбинацијом прогестерона и прогестагена.

Закључак Рана дијагноза Шихановог синдрома је од есенцијалног значаја. Питуитарна инсуфицијенција код ових пацијената има велики диверзитет у презентацији, што понекад може да резултира комом и смрћу.

Кључне речи: постпартална хеморагија; Шиханов синдром; панхипопитуитаризам

INTRODUCTION

Hyponatremia defined as sodium level < 135 mmol/l is a frequent electrolyte disorder, and it can be found in patients with endocrinopathies [1]. In hospital setting the incidence of hyponatremia is as high as 30% [2, 3]. Most commonly seen endocrinopathies together with euvolemic hyponatremia are Syndrome of inappropriate antidiuretic hormone secretion (SIADH), adrenal insufficiency and hypothyroidism [3]. Sheehan syndrome (ShS) is (pan)hypopituitarism on the grounds of postpartum pituitary infarction due to massive obstetrical hemorrhage. Signs and symptoms of ShS are mild and nonspecific, so the diagnosis can be easily missed or delayed [4]. Nationwide retrospective study in Iceland found the incidence of ShS of 5.1 per 100,000 females, while according to KIMS database (Pfizer international metabolic database) the incidence of ShS was found to be 3.1 in 1034 patients with growth hormone deficiency. Occurrence of ShS in developed countries is estimated to be exceedingly rare due to highly developed obstetrical care [5]. Here we present a case of acute onset of hyponatremia in patient who experienced hemorrhage during labor.

CASE REPORT

A 39-year-old female patient was admitted to hospital 5 days after parturition because of altered sensorium. Five days earlier she had given birth to a healthy newborn, but the labor had been complicated with extensive obstetrical hemorrhage. On admission, the patient was adynamic and confused, with signs of anemia but without signs of obstetrical bleeding. She reported that lactation was not established. She did not have polyuria or polydipsia. Blood was drawn for initial laboratory tests; the results are shown in Table 1. Due to severe overt hyponatremia, she was treated with 3% saline solution and further investigation was indicated. The results of endocrinological tests are shown in Table 2. Endocrinological testing showed panhypopituitarism. Parenteral hydrocortisone was introduced, and after a few days,

levothyroxine was added. All the signs and symptoms of severe hyponatremia resolved after the therapy and did not appear again after the hydrocortisone initiation. Magnetic resonance imaging (MRI) of the pituitary gland was done, and it revealed enlarged pituitary with apoplexy without bleeding (Image 1). On subsequent ambulatory check-ups panhypopituitarism persisted and replacement dose of estrogen and progesterone was given, along with growth hormone therapy initiation. So far, we have been following this patient for three years and panhypopituitarism seems to be definite. She is feeling well and is asymptomatic.

DISCUSSION

ShS can be a life-threatening condition thus making a delay in diagnosis detrimental. It emerges because of extensive postpartum hemorrhage which leads to pituitary hypoperfusion and necrosis [6, 7]. Nowadays ShS diagnosis is rare in developed countries, but in under-developed and developing countries it can be seen more often. With improving obstetrical care, the incidence of ShS is lessening, but more than 40 years ago the prevalence of this condition was around 100-200 per 100000 females [8]. Miljić et al. presented a retrospective study on 260 patients with hypopituitarism treated in their specialized endocrinological unit in a decade, and among those patients 2 had ShS [9]. Due to the rarity of this condition, nowadays in countries with well-developed medical care the data regarding the incidence of ShS is not fully established [4, 8, 10]. Signs and symptoms of ShS are nonspecific and gradual in onset. The time from onset to the diagnosis is 1 month to 27 years [11-13]. Our patient had the abrupt onset of signs and symptoms of severe overt hyponatremia due to central adrenal insufficiency. Earlier reports of deaths due to diminished cortisol level in unrecognized partial or complete hypopituitarism after labor emphasize the need to reintroduce ShS as possible cause of rapid onset of worsening state in females after delivery

[14-16]. Hyponatremia in ShS is mainly the consequence of central adrenal insufficiency i.e., the lack of cortisol. It is known that SIADH is the most common reason for euvolemic hyponatremia. There are clear diagnostic criteria for SIADH, nevertheless it is not always the case that the central adrenal insufficiency is priorly excluded [17-19]. Further contribution to the severity of hyponatremia comes from hypothyroidism as a part of hypopituitarism in the presented patient. Hyponatremia in isolated hypothyroidism is rare, and mostly the consequence of primary hypothyroidism. Proposed mechanism for the hyponatremia in hypothyroid patients is the elevation of antidiuretic hormone together with mild renal impairment [20-23]. Symptomatic hyponatremia should be urgently solved with intravenous 3% saline solution according to current guidelines, having in mind that too fast elevation of sodium can result in pontine myelinolysis [1, 24, 25, 26]. Timely diagnosis of ShS is needed in order to initiate adequate hormonal supplementation, and the hydrocortisone and levothyroxine are of vital significance.

ShS is a rare condition in developed countries and the significance of the risk it carries might be neglected. Central adrenal insufficiency can be component of ShS, thus contributing to the severity of syndrome. With timely diagnosis and adequate therapy, significant morbidity and, in some cases, mortality might be avoided.

Ethical standards: Written consent for publication of this article obtained from the patient.

Conflict of interest: None declared.

REFERENCES

1. Spasovski G, Vanholder R, Allolio B, Annane D, Ball S, Bichet D, Decaux G, Fenske W, Hoorn EJ, Ichai C, Joannidis M, Soupart A, Zietse R, Haller M, van der Veer S, Van Biesen W, Nagler E; Hyponatraemia Guideline Development Group. Clinical practice guideline on diagnosis and treatment of hyponatraemia. *Nephrol Dial Transplant*. 2014 Apr;29 Suppl 2:i1-i39. doi: 10.1093/ndt/gfu040. Epub 2014 Feb 25. Erratum in: *Nephrol Dial Transplant*. 2014 Jun;40(6):924. PMID: 24569496.
2. Zhang X, Li XY. Prevalence of hyponatremia among older inpatients in a general hospital. *Eur Geriatr Med*. 2020 Aug;11(4):685-692. doi: 10.1007/s41999-020-00320-3. Epub 2020 May 5. PMID: 32372184; PMCID: PMC7438367.
3. Diker-Cohen T, Rozen-Zvi B, Yelin D, Akirov A, Robenshtok E, Gafer-Gvili A, Shepshelovich D. Endocrinopathy-induced euvolemic hyponatremia. *Intern Emerg Med*. 2018 Aug;13(5):679-688. doi: 10.1007/s11739-018-1872-4. Epub 2018 May 22. PMID: 29790126.
4. Diri H, Karaca Z, Tanriverdi F, Unluhizarci K, Kelestimur F. Sheehan's syndrome: new insights into an old disease. *Endocrine*. 2016 Jan;51(1):22-31. doi: 10.1007/s12020-015-0726-3. Epub 2015 Sep 1. PMID: 26323346.
5. Kristjansdottir HL, Bodvarsdottir SP, Sigurjonsdottir HA. Sheehan's syndrome in modern times: a nationwide retrospective study in Iceland. *Eur J Endocrinol*. 2011 Mar;164(3):349-54. doi: 10.1530/EJE-10-1004. Epub 2010 Dec 23. PMID: 21183555.
6. Rahmani Tzvi-Ran I, Olchowski J, Fraenkel M, Bashiri A, Barski L. A rare cause of postpartum acute hyponatremia. *Endocrinol Diabetes Metab Case Rep*. 2019 Mar 15;2019:18-0124. doi: 10.1530/EDM-18-0124. Epub ahead of print. PMID: 30875679; PMCID: PMC6432973.
7. Mandal S, Mukhopadhyay P, Banerjee M, Ghosh S. Clinical, Endocrine, Metabolic Profile, and Bone Health in Sheehan's Syndrome. *Indian J Endocrinol Metab*. 2020 Jul-Aug;24(4):338-342. doi: 10.4103/ijem.IJEM_345_20. Epub 2020 Aug 27. PMID: 33088757; PMCID: PMC7540820.
8. Keleştimur F. Sheehan's syndrome. *Pituitary*. 2003;6(4):181-8. doi: 10.1023/b:pitu.0000023425.20854.8e. PMID: 15237929.
9. Miljic D, Doknic M, Stojanovic M, Nikolic-Djurovic M, Petakov M, Popovic V, Pekic S. Impact of etiology, age and gender on onset and severity of hyponatremia in patients with hypopituitarism: retrospective analysis in a specialised endocrine unit. *Endocrine*. 2017 Nov;58(2):312-319. doi: 10.1007/s12020-017-1415-1. Epub 2017 Sep 14. PMID: 28913704.
10. Tanriverdi F, Kelestimur F. Classical and non-classical causes of GH deficiency in adults. *Best Pract Res Clin Endocrinol Metab*. 2017 Feb;31(1):3-11. doi: 10.1016/j.beem.2017.02.001. Epub 2017 Feb 23. PMID: 28477730.
11. Gokalp D, Alpagat G, Tuzcu A, Bahceci M, Tuzcu S, Yakut F, Yildirim A. Four decades without diagnosis: Sheehan's syndrome, a retrospective analysis. *Gynecol Endocrinol*. 2016 Nov;32(11):904-907. doi: 10.1080/09513590.2016.1190331. Epub 2016 Jun 2. PMID: 27252045.
12. Gei-Guardia O, Soto-Herrera E, Gei-Brealey A, Chen-Ku CH. Sheehan syndrome in Costa Rica: clinical experience with 60 cases. *Endocr Pract*. 2011 May-Jun;17(3):337-44. doi: 10.4158/EP10145.OR. PMID: 21041170.
13. Diri H, Tanriverdi F, Karaca Z, Senol S, Unluhizarci K, Durak AC, Atmaca H, Kelestimur F. Extensive investigation of 114 patients with Sheehan's syndrome: a continuing disorder. *Eur J Endocrinol*. 2014 Sep;171(3):311-8. doi: 10.1530/EJE-14-0244. Epub 2014 Jun 10. PMID: 24917653.
14. Windpessl M, Karrer A, Schwarz C. Acute Hyponatremia in Puerperium: Sheehan's Syndrome. *Am J Med*. 2018 Apr;131(4):e147-e148. doi: 10.1016/j.amjmed.2017.11.032. Epub 2017 Dec 15. PMID: 29253367.
15. Jose M, Amir S, Desai R. Chronic Sheehan's Syndrome - A Differential to be Considered in Clinical Practice in Women with a History of Postpartum Hemorrhage. *Cureus*. 2019 Dec 4;11(12):e6290. doi: 10.7759/cureus.6290. PMID: 31938584; PMCID: PMC6942501.
16. Garrahy A, Agha A. How should we interrogate the hypothalamic-pituitary-adrenal axis in patients with suspected hypopituitarism? *BMC Endocr Disord*. 2016 Jun 17;16(1):36. doi: 10.1186/s12902-016-0117-7. PMID: 27316460; PMCID: PMC4912809.
17. Taniguchi J, Sugawara H, Yamada H, Yoshida K, Kurihara I, Yoshida M, Ishii A, Fukuchi T, Fujimoto WY. Adrenal crisis precipitated by influenza A led to the diagnosis of Sheehan's syndrome 18 years after postpartum hemorrhage. *Clin Case Rep*. 2020 Sep 18;8(12):3082-3087. doi: 10.1002/ccr3.3355. PMID: 33363885; PMCID: PMC7752366.
18. Cuesta M, Garrahy A, Slattery D, Gupta S, Hannon AM, Forde H, McGurran K, Sherlock M, Tormey W, Thompson CJ. The contribution of undiagnosed adrenal insufficiency to euvolemic hyponatraemia: results of a large prospective single-centre study. *Clin Endocrinol (Oxf)*. 2016 Dec;85(6):836-844. doi: 10.1111/cen.13128. Epub 2016 Jul 12. PMID: 27271953.

19. Cuesta M, Thompson CJ. The syndrome of inappropriate antidiuresis (SIAD). *Best Pract Res Clin Endocrinol Metab.* 2016 Mar;30(2):175-87. doi: 10.1016/j.beem.2016.02.009. Epub 2016 Feb 27. PMID: 27156757.
20. Wolf P, Beiglböck H, Smajjs S, Wrba T, Rasoul-Rockenschaub S, Marculescu R, Gessler A, Luger A, Winhofer Y, Krebs M. Hypothyroidism and Hyponatremia: Rather Coincidence Than Causality. *Thyroid.* 2017 May;27(5):611-615. doi: 10.1089/thy.2016.0597. Epub 2017 Apr 19. PMID: 28351291.
21. Nagata T, Nakajima S, Fujiya A, Sobajima H, Yamaguchi M. Prevalence of hypothyroidism in patients with hyponatremia: A retrospective cross-sectional study. *PLoS One.* 2018 Oct 11;13(10):e0205687. doi: 10.1371/journal.pone.0205687. PMID: 30308047; PMCID: PMC6181416.
22. Ergin AB, Bena J, Nasr CE. Hypothyroidism and hyponatremia: simple association or true causation. *Open J Thyroid Res* 2017;1(1):012-016.
23. Pantalone KM, Hatipoglu BA. Hyponatremia and the Thyroid: Causality or Association? *J Clin Med.* 2014 Dec 26;4(1):32-6. doi: 10.3390/jcm4010032. PMID: 26237016; PMCID: PMC4470237.
24. Hoorn EJ, Zietse R. Diagnosis and Treatment of Hyponatremia: Compilation of the Guidelines. *J Am Soc Nephrol.* 2017 May;28(5):1340-1349. doi: 10.1681/ASN.2016101139. Epub 2017 Feb 7. PMID: 28174217; PMCID: PMC5407738.
25. Chifu I, Gerstl A, Lengenfelder B, Schmitt D, Nagler N, Fassnacht M, Weismann D. Treatment of symptomatic hyponatremia with hypertonic saline: a real-life observational study. *Eur J Endocrinol.* 2021 May;184(5):647-655. doi: 10.1530/EJE-20-1207. PMID: 33635825; PMCID: PMC8052513.
26. Baek SH, Jo YH, Ahn S, Medina-Liabres K, Oh YK, Lee JB, Kim S. Risk of Overcorrection in Rapid Intermittent Bolus vs Slow Continuous Infusion Therapies of Hypertonic Saline for Patients With Symptomatic Hyponatremia: The SALSA Randomized Clinical Trial. *JAMA Intern Med.* 2021 Jan 1;181(1):81-92. doi: 10.1001/jamainternmed.2020.5519. PMID: 33104189; PMCID: PMC7589081.

Table 1. Initial blood results

| | |
|--------------------------|-------|
| Sodium (mmol/l) | 103 |
| Potassium (mmol/) | 3.7 |
| Chlorine (mmol/l) | 72 |
| Hemoglobin (g/l) | 105 |
| RBC ($\times 10^{12}$) | 3.7 |
| WBC ($\times 10^9$) | 11.06 |
| Hematocrit (%) | 27.9 |
| CRP (mg/L) | 29.4 |

RBC – red blood cells; WBC – white blood cells; CRP – C-reactive protein

Table 2. Endocrinological test results

| | |
|---|-------|
| FSH (IU/L) | < 0.1 |
| LH (IU/L) | < 0.5 |
| PRL (ng/mL) | 12.2 |
| ACTH (pg/mL) | 3 |
| hGH (ng/mL) | 0.12 |
| IGF-1 (ng/mL) | 134.8 |
| Cortisol 8 a.m. (nmol/L) | 14.5 |
| 24-hour urine sodium excretion (mmol/day) | 83 |
| Anti-TPO Ab (IU/ml) | 1.4 |
| Anti-Tg Ab (ng/ml) | 18.6 |

FSH – follicle-stimulation hormone; LH – luteinizing hormone; PRL – prolactin; ACTH – adrenocorticotrophic hormone; hGH – human growth hormone; IGF-1 – insulin-like growth factor 1; Anti – TPO Ab, – thyroid peroxidase antibody; Anti – Tg Ab – antithyroglobulin antibodies

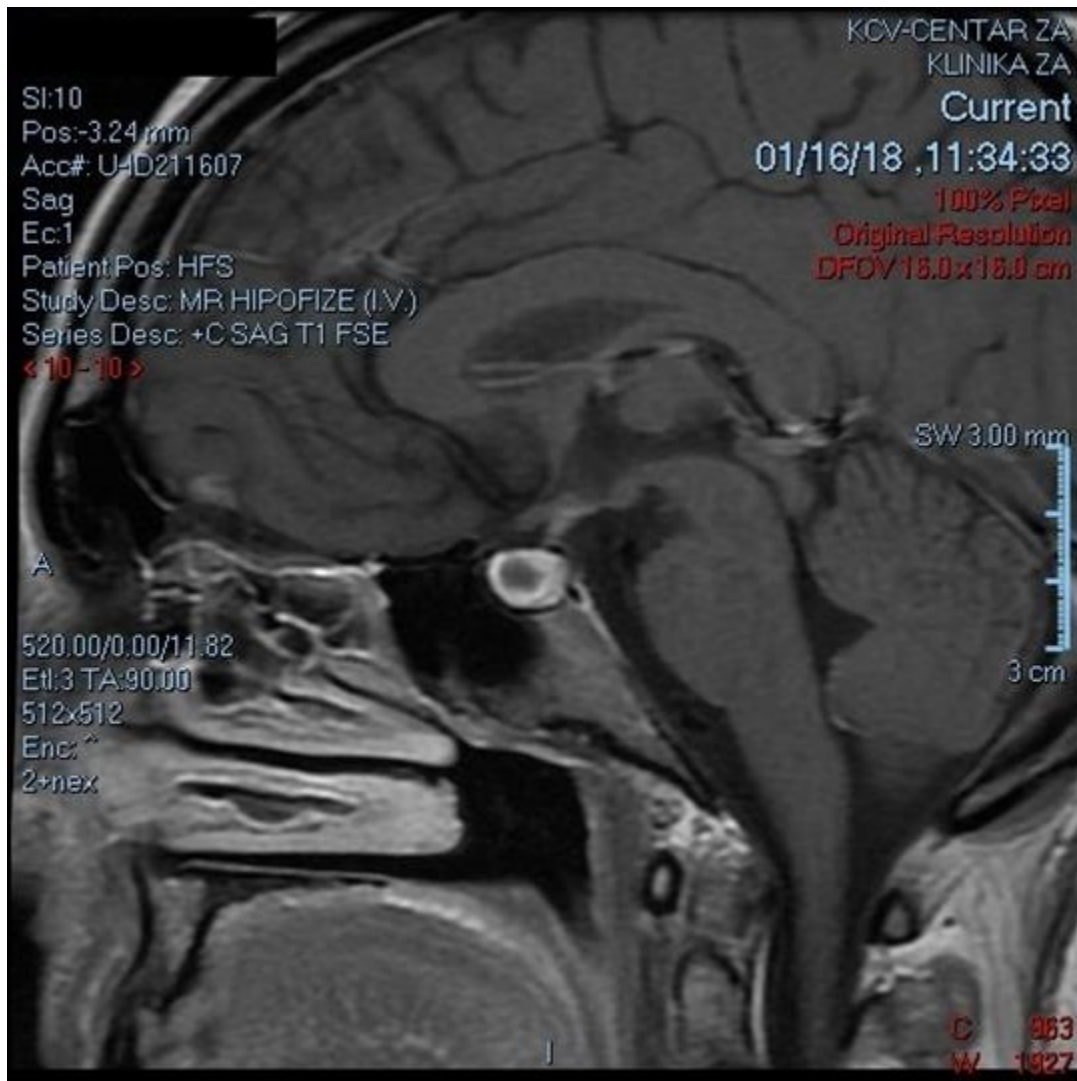


Figure 1. Enlarged pituitary with apoplexy without bleeding